

Case Report**PROLONGED QTC INTERVAL AND TORSADES DE POINTES INDUCED BY MOXIFLOXACIN**

Mohammad Iftikhar Adil¹, Mir AttaUllah², Meena Gul³, Sartaj Khan⁴

¹Department of Pharmacology, Gajju Khan Medical College, Swabi, Pakistan

²Department of Pathology, Gajju Khan Medical College, Swabi, Pakistan

³Department of Physiology, Gajju Khan Medical College, Swabi, Pakistan

⁴Department of Community Medicine, Gajju Khan Medical College, Swabi, Pakistan

ABSTRACT

(TdP) is a particular kind of polymorphic ventricular tachycardia that may be fatal if it persists and occurs in conjunction with [QT interval] prolongation. A broad variety of medications that are often used in clinical practice may lengthen the [QT interval], which can cause TdP and put the patient's life in jeopardy. [Moxifloxacin] is one of these medications that is known for prolonging the [QT interval] and causing TdP, along with other fluoroquinolones. As a result, we are presenting the case of a 60-year-old female who was treated with [Moxifloxacin] for acute gastroenteritis and a chest infection and later developed [QTc] prolongation and TdP.

Keywords: Corrected,QT interval, QTc, Moxifloxacin, Torsades de pointes, TdP

INTRODUCTION

The potentially lethal form of polymorphic ventricular tachycardia known as torsades de pointes (TdP) requires urgent medical attention. TdP may originate from an elongated [QT interval], either genetic or environmental. Medications that delay ventricular repolarization are a common source of acquired cases. The ^{1,2}[QT interval] on an electrocardiogram refers to the space between the beginning of the Q wave and the end of the T wave. Time to repolarization after ventricular depolarization is shown. The 3 [QT interval]'s QRS complex and ST interval are divisible. The ST segment and T wave comprise the ST interval. QT prolongation may come from prolonged depolarization or repolarization. The ECG shows a larger QRS complex due to increased depolarization. A longer ECG ST interval suggests a longer repolarization time. A lengthy ST interval might occur from a long ST segment or T wave. Lead AVR, AVF, V5, V6, and V4 may measure [QT interval] instead of Lead II. ⁵ If this is impossible, the lead with the best [QT interval] measurement accuracy shall be chosen. QT

changes with heart rate and has an inverse relationship to it, hence corrected QT should be used instead. QT lengthens with heart rate falls and shortens with heart rate rises. The [QT interval] at 60 bpm is estimated to correct QT. ECGs with 60 beats per minute heart rates indicate an individual's absolute [QT interval] value. Bazett's formula 6 is the most popular correction formula for [QTc] estimates: $QTc = \frac{QT}{(RR)^{0.75}}$ Electrolyte imbalance, especially hypocalcemia, hypokalemia, and hypomagnesaemia; diabetes; abnormal drug elimination compared to oral administration; old age; gender; cardiovascular conditions like ischemia, infarction, congestive heart failure, cardiomyopathy, atrial fibrillation, bradycardia; obesity; acute intracranial hypertension; QT interval prolongation is predisposed by the number 7 and genetic polymorphism.^{8,9} Rapid intravenous infusion of proarrhythmogenic and torsadogenic medicines prolongs QT or TdP. QT intervals are often lengthened by medication. QT prolongation has been related to several medicines. Drug-induced QT lengthening is often caused by blocking the I_{Kr}, a fast-moving component of the delayed rectifier current that restores the action potential to the resting membrane potential.

Correspondence:

Dr. Mohammad Iftikhar Adil,

Assistant Professor,

Department of Pharmacology, Gajju Khan Medical College, Swabi, Pakistan

Cell: 0300-5217818

Email: iftikharadil22@yahoo.com

Citations: Mohammad Iftikhar Adil, Mir AttaUllah, Meena Gul, & Sartaj Khan. (2020). PROLONGED QTC INTERVAL AND TORSADES DE POINTES INDUCED BY MOXIFLOXACIN: A Case Report. Journal of Bacha Khan Medical College, 1(01), Page No. 54–57. <https://doi.org/10.69830/jbkmc.v1i01.84>

Thioridazine, cisapride, terfenadine, astemizole, and sertindole suppress I_{Kr} . All these variables impede

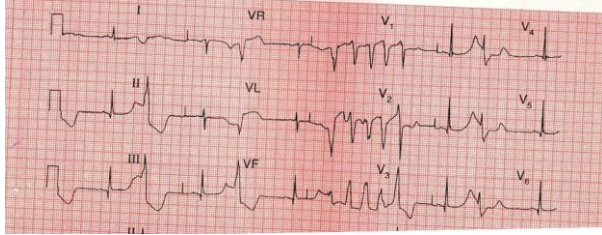


Figure 1: ECG showing polymorphic ventricular tachycardia TdP

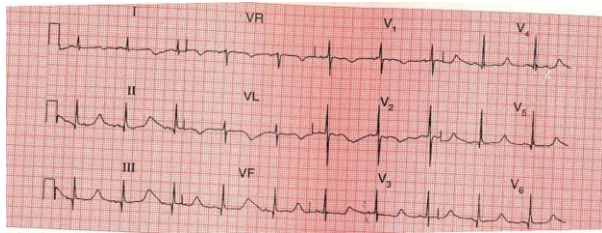


Figure 2: ECG showing QTc interval prolongation. repolarization. ¹⁰

Human ERG encodes the alpha subunit of the ion channel regulating protein (I_{Kr}). QT prolongation may result from hERG channel trafficking changes. Arsenic trioxide, pentamidine, and scorpion toxin inhibit housekeeping proteins from binding to the hERG channel. Failure to transport mature channels to the cell membrane slows repolarization and prolongs QT.¹¹ These sodium channel blockers delay depolarization and inhibit the I_{Na+} current, causing a big QRS complex on the EKG. Danisetrone, a 5HT₃ antagonist, is highly torsadogenic, as are tricyclic antidepressants, antiemetics, local anesthetics, class 1A and 1C antiarrhythmics like quinidine and procainamide, and other drugs in these classes.¹² Because they expand the QRS complex, these medications extend the QT interval.¹³ Some Na^+ channel blockers also reduce I_{Kr} currents, extending QT and widening QRS complexes. Cocaine and similar drugs block potassium-sodium channels. Cocaine addicts risk QT prolongation and TdP.¹⁴

Mefloquine, bepridil, and azimilide inhibit the potassium rectifier current's fast and slow components to delay cardiac repolarization, extending QT.¹⁵ By inhibiting IKs, halothane, isoflurane, enflurane, and sevoflurane may increase [QT interval].¹⁶ 2 adrenoceptor agonists including epinephrine, salbutamol, terbutaline, and salmeterol reduce blood potassium and block I_{Kr} , extending the

QT interval.¹⁷ The heart takes longer to repolarize when diuretics like furosemide and thiazide lower potassium and magnesium levels in the blood. There's no immediate magnesium impact. Hypokalemia and hypocalcemia extend [QT interval]. ECG hypokalemia occurs when blood potassium drops below 2.7meq/L.¹⁸ Insulin prolongs QT via boosting sympathetic activity and lowering blood potassium with hypoglycemia.¹⁹ The [QT interval] is lengthened by fluoroquinolones and macrolides. Drugs with QT prolongation have been withdrawn from US sales. When the I_{Kr} is inhibited, the ECG shows a U wave, which activates an early after depolarization current during phases 2 and 3. When these levels rise too high, ventricular arrhythmia may cause re-entry and torsade de pointes. Due to a lack of delayed rectifier potassium current, ventricular M cells in the deep endocardial and middle myocardial layers are more susceptible.²⁰ French "twisting around," or "torsade de pointes." Polymorphic ventricular tachycardia twists the electrical axis. This RR interval has a 200-250 bpm heart rate. Before initiating TdP, the QT interval should be 500 ms. QRS complex amplitude crescendo-decrescendo. Long or short RR periods preceding TdP are conceivable. Syncope, disorientation, and low blood pressure may result from hemodynamically unstable TdP. Most TdP episodes revert to normal sinus rhythm within seconds, but uncommon cases might develop to ventricular fibrillation, which can cause sudden cardiac death if untreated. Polymorphic ventricular tachycardia prolongs QT and induces R on T, where R represents ventricular depolarization during relative refractory time. The T wave's tail ends repolarization. QT prolongation is a key risk factor for TdP, however most drug-induced QT prolongation does not cause it.²¹ Avoiding ventricular fibrillation and abrupt cardiac mortality requires TdP therapy. TdP therapy begins with magnesium sulphate after defibrillation.²²

Since 1985, quinolones have been widely used. They work against many bacteria, even those resistant to most antibiotics. Because they might cause cardiac difficulties in certain people, Gatifloxacin, Trovofloxacin, Sparfloxacin, and Grepafloxacin have been pulled off stores. Moxifloxacin, a strongly recommended fluoroquinolone, prolongs the QTc interval and increases the risk of torsades de pointes. In the hospital, a patient with severe gastroenteritis and a chest infection developed TdP while receiving [Moxifloxacin].

CASE REPORT

Prolonged qtc interval and torsades de pointes.....

A 60-year-old lady who had loose movements, abdominal discomfort, a fever, and a cough was brought to the medical unit. She has no noteworthy prior experiences, and her family has never had a sudden cardiac death. Her temperature was 100 degrees Fahrenheit, her pulse rate was 60 beats per minute, her blood pressure was 110/80 mmHg, and a thorough physical examination revealed mild to moderate dehydration. The remainder of the physical examination and systemic exam were uneventful. Serum potassium was 3.5 meq/l, sodium was 142 meq/l, and chloride was 102 meq/l, according to the first laboratory results. Her kidney function tests, LFTs, and CBC all fell within acceptable limits. She was given omeprazole 40mg intravenously daily, metronidazole 500mg every 8 hours, and [Moxifloxacin] 400mg intravenously. The patient began experiencing dizziness, syncopal episodes, palpitations, and sweating on the third day. The ECG was performed immediately and revealed polymorphic ventricular tachycardia, also known as torsades de pointes. The patient's condition improved when I/V [Moxifloxacin] was quickly terminated, and I/V fluids and magnesium sulphate were administered. A repeat ECG revealed a [QTc] of around 650 ms. The heart rate monitor was fastened. The patient was then started on 1 gm of i/v ceftriaxone twice day, and the remainder of the therapy was continued. The submitted serum electrolytes were within normal limits. The [QTc] interval was decreasing and was 490ms on the fourth day. Omeprazole and metronidazole were discontinued. The [QTc] interval restored to 460 ms after 3 hours, which is a typical number for women. The [QTc] was elevated to 490ms after 3 hours of replacing ceftriaxone with i/v [Moxifloxacin] the next day, and the condition persisted for 48 hours. No torsades took place.

DISCUSSION

(Moxifloxacin) is a widely recommended medication because it is a broad spectrum antibiotic with a long half-life, once daily dosing, and is extremely effective against a variety of pathogens, particularly respiratory infections. One of the major side effects that may cause torsades de pointes, a rare but lethal condition, is [QT interval] lengthening. Despite the fact that [Moxifloxacin] was the primary reason in this case's TdP, the patient also had additional risk factors, including advanced age, obesity, female gender, and borderline Potassium content. According to Kounas SP in 2005, metronidazole may also subtly lengthen the

[QTc] interval by inhibiting cytochrome P450. According to a medical letter on medications and treatments from December 2016, omeprazole may only lengthen the [QTc] interval in cases of hypomagnesemia, [hypokalemia], and [hypocalcemia]; however, in this case, the patient's electrolytes were within normal limits. the [QTc] interval lengthened when metronidazole and omeprazole were withdrawn and just [Moxifloxacin] was resumed. [Moxifloxacin] was the cause of the TdP and [QTc] prolongation. As a result, it is advised that individuals with risk factors avoid using [Moxifloxacin] and have a baseline ECG before taking any medication to check for QT prolongation.

CONCLUSION

[Moxifloxacin] prolongs the [QTc] interval, however when combined with other risk factors and medications that also lengthen the [QTc] interval, the risk of torsades de pointes rises, hence prescribing [Moxifloxacin] for polypharmacy should be avoided.

ACKNOWLEDEMENT

We appreciate Mr. Yousaf Khan and Mr. Ijaz Khan's assistance in completing this report.

REFERENCE

- 1-Owens RC Jr. Risk assessment for antimicrobial agent-induced [QTc] interval prolongation and torsades de pointes. *Pharmacother*,2001; 21:pp 301319
1. Owens RC Jr. Risk assessment for antimicrobial agent-induced [QTc] interval prolongation and torsades de pointes. *Pharmacother*,2001; 21:pp 301-319
2. Amankwa K, Krishnan CK, Tisdale JE. Torsade de pointes associated with fluoroquinolones: Importance of concomitant risk factors. *Clin Pharmacol Ther* 2004 ; 75(3): pp 242-7.
3. Li EC, Esterly JS, Pohl S. Drug induced [QT interval] Prolongation: considerations for Clinicians. *Pharmacotherapy* 2010; 30: pp 684-70
4. Bednar MM, Harrigan EP, Anziano RJ, Camm AJ, Ruskin JN. The QT interv prog cardiovasc Dis 2001;43:pp1-45.
5. Salvi V, Karnad DR, Kerkar V, Panicker GK, Manohar D, Natekar M. Choice of an alternative lead for [QT interval] measurement in serial ECGs when lead II is not suitable for analysis. *Indian heart journal* xxx 2012: pp 1-6.

6. Bazett HC. An analysis of the time relations of electrocardiogram. *Heart* (7)1920: pp; 353-370.
7. Redfern WS, Carlsson L, Davis AS. Relationships between preclinical electrophysiology, clinical [QT interval] prolongation and torsade de pointes for a broad range of drugs: evidence for a provisional safety margin in drug development. *Cardiovasc Res* 2003; 58: pp 32-45.
8. Locati EH, Zareba W, Moss AJ. Age- and sex-related differences in clinical manifestations in patients with congenital long QT syndrome: findings from the International LQTS Registry. *Circulation* 1998; 97: pp 2237-2244
9. Reardon M, Malik M. [QT interval] change with age in an overtly healthy older population. *Clin Cardiol* 1996; 19: pp 949-952
10. Kuryshv YA, Ficker E, Wang L (2005). Pentamidine-induced long QT syndrome and block of HERG trafficking. *J Pharmacol Exp Ther*; 312: pp 316-323.
11. Chouabe C, Drici MD, Romey G, Barhanin J (2000). Effects of calcium channel blockers on cloned cardiac K⁺ channels IKr and IKs. *Therapie*; 55:pp195-202.
12. Nau C, Seaver M, Wang SY, Wang GK (2000). Block of human heart hH1 sodium channel by Amitriptyline. *J Pharmacol Exp Ther*; 292: pp 1015-1023.
13. Gamouras GA, Monir G, Plunkitt K, Gursoy S, Dreifus LS. Cocaine abuse repolarization abnormalities and ventricular arrhythmias. *Am J Medsci* 2000;320: pp 9-12.
14. Kang J, Chen XL, Wang L, Ramp D. Interactions of the antimalarial drug mefloquine With the human cardiac potassium channels KvLQT1/mink and HERG. *J Pharmacol Exp Ther* 2001; 299: pp 290-296.
15. Shibata S, Ono K, Iijim T. Sevoflurane inhibition of the slowly activating delayed rectifier K⁺ current in guinea pig ventricular cells. *J Pharmacol* 2004; pp 363-373.
16. Kuusela TA, Jatti TT, Tahvanainen KU, Kaila TJ (2005). Prolongation of [QT interval] by Terbutaline in healthy subjects. *J Cardiovasc Pharmacol*; 45:pp175-181.
17. Singh BN, Hollenberg NK, Poole-Wilson PA, Robertson JI (1992). Diuretic-induced potassium and magnesium deficiency: relation to drug-induced QT prolongation, cardiac arrhythmias and sudden death. *J Hypertens*; 10: pp301-316
18. Antzelevitch C, Sicouri S (1994). Clinical relevance of cardiac arrhythmias generate Afterdepolarizations. Role of M cells in the generation of U waves, triggered activity and torsade de pointes. *J Am Coll Cardiol*; 23(1): pp 259-77
19. Schwartz PJ, Stramba Badiale M, Napolitano C. The long QT syndrome. In: Zipes DP, Jalife I (eds): *Cardiac Electrophysiology From Bench to Bedside*. Philadelphia: Wb Saunders 2000: pp 788-811.
21. Hoshino K, Ogawa K, Hishitani T, Isobe T, Etoh Y (2006). Successful uses of magnesium Sulphate for torsades de pointes in children with long syndrome. *Pediatr Int* 48 (2): pp112-7.
22. Lannini PB, Tilloson GS (2001). Evaluating the risk of cardiac toxicity *Pharmacotherapy*, 21: pp 261-262.

Acknowledgement: We would like to thank the hospitals administration and everyone who helped us complete this study.

Disclaimer: Nil

Conflict of Interest: There is no conflict of interest.

Funding Disclosure: Nil

Authors Contribution

Concept & Design of Study: Mohammad Ifikhar Adil1

Drafting: Mir AttaUllah2

Data Analysis: Mir AttaUllah2

Critical Review: Meena Gul3

Final Approval of version: Sartaj Khan4



Open Access: This article is licensed under a Creative Commons Attribution 4.0 International License, which permits use, sharing, adaptation, distribution and reproduction in any medium or format, as long as you give appropriate credit to the original author(s) and the source, provide a link to the Creative Commons license, and indicate if changes were made. The images or other third party material in this article are included in the article's Creative Commons license, unless indicated otherwise in a credit line to the material. If material is not included in the article's Creative Commons license and your intended use is not permitted by statutory regulation or exceeds the permitted use, you will need to obtain permission directly from the copyright holder. To view a copy of this license, visit <http://creativecommons.org/licenses/by/4.0/>. © The Author(s) 2020