

Case Report

A COMPARATIVE STUDY OF X-RAY AND CT IN MEDICO LEGAL TRAUMA

Abdul Aziz Zia

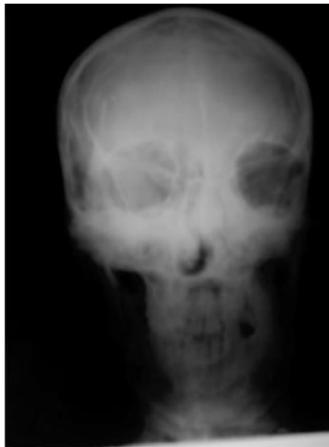Department of Radiology, Bacha Khan Medical College, MMC Mardan, Pakistan

BACKGROUND:

Computed Tomography [CT] is very valuable in visualizing bone fractures and other lesions. It can be used to confirm medico legal cases of controversial nature. The purpose of this study was to compare the findings of CT and X Ray to provide accurate diagnosis, resolve the issues between the concerned parties and help the court to decide in medico legal cases. The diagnosis was more confirmed and extent of the fractures was quantified by 3-dimensional CT scan.

FEW CASES

Case 1 Name "S"



X-ray skull normal

Correspondence:

Dr. Abdul Aziz Zia

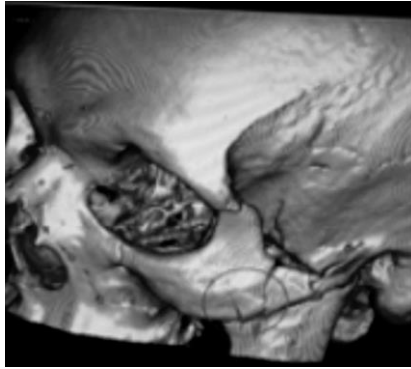
Department of Radiology,

Bacha Khan Medical College, MMC Mardan

Cell: 0333-9135453

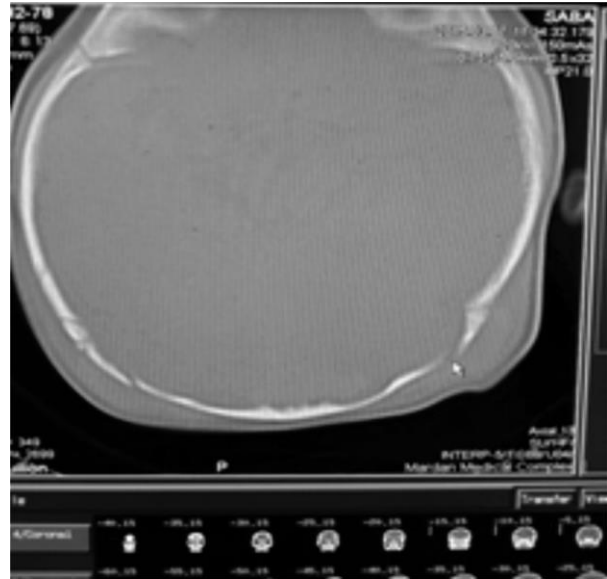
Email: abdulazizzia@gmail.com

CT Fracture and blood collection in left maxillary sinus

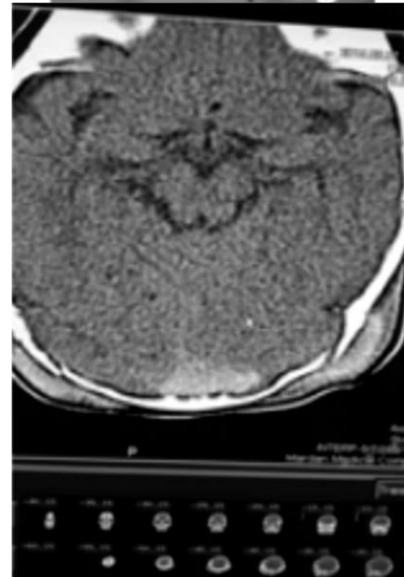

T 3 D CT confirms fracture he above mentioned case was a person name “S” age 45 years was referred from RHC Sher Garh Dist. Mardan to Mardan Medical Complex Mardan [MMC]. It was a medico legal case being hit on head and face this morning. He was having X- Ray skull [AP, Lat views] which was reported as normal.

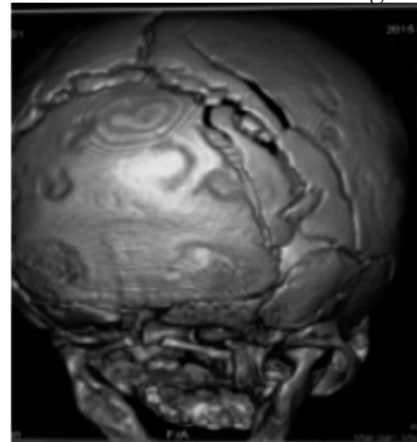
The injured person was bleeding from nose. His left eye was red and swollen. The CMO on duty agreed with X Ray report of the referring MO RHC as SIMPLE because there was no visible fracture in the X Ray. CMO provided first aid treatment and sent the patient home. The pain of the patient increased and still had epistaxis. He was brought on the next morning to OPD of MMC. The consultant examined and advised CT skull. The CT findings in bone window were three fractures of Lt. Maxillary bone and collection [blood, hematoma] in the Lt. Maxillary sinus. It was more evident in 3 D CT. The patient was admitted in ENT unit for proper treatment. The review of the X Ray films by the radiologist indicated even the same findings as was reported by the CMO but CT scan confirmed the fracture. The MLC report was changed from SIMPLE to GREVIOUS.

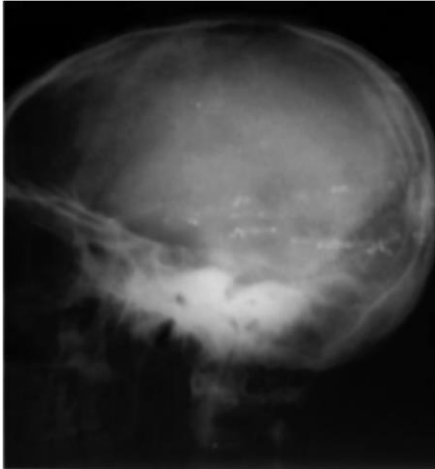


CT- Fracture occipital bone



CT- Fracture and haemorrhage





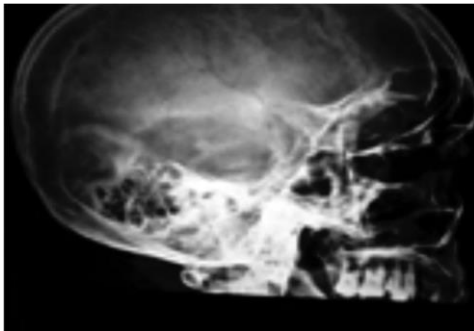
X-ray normal 3 D CT-- Fractureoccipital bone

A mother and a child name Saba of three years had trauma to their different parts of body were brought to OPD. The mother was having some bruises on back while the child was semi unconscious. The case was medico legal. The X ray of mother Lumbar spine and skull of the child were reported normal. They were advised treatment and sent home. The mother pain subsided with treatment however condition of the child deteriorated gradually.

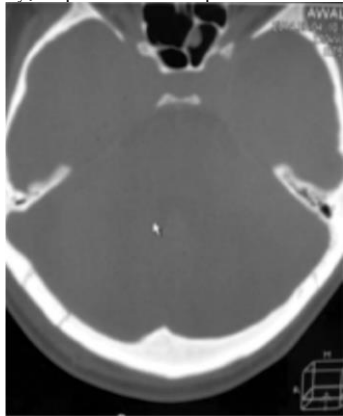The child brought to MMC to consult pediatrician. CT brain was advised. There was a tiny fracture of occipital bone with extradural hemorrhage. The MLC report was corrected accordingly.

CASE 3

Hasan

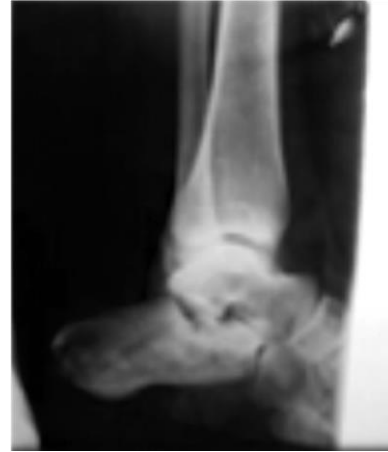

X ray, reported as depressed fracture

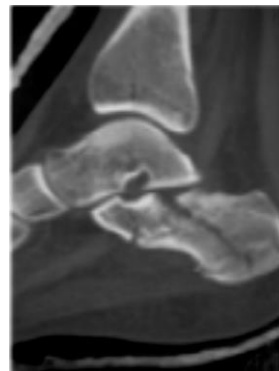
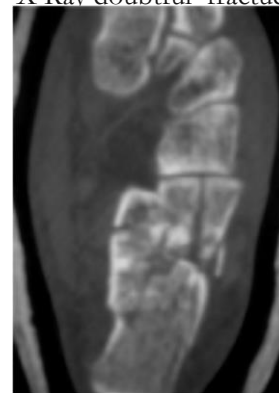
CT- skull normal

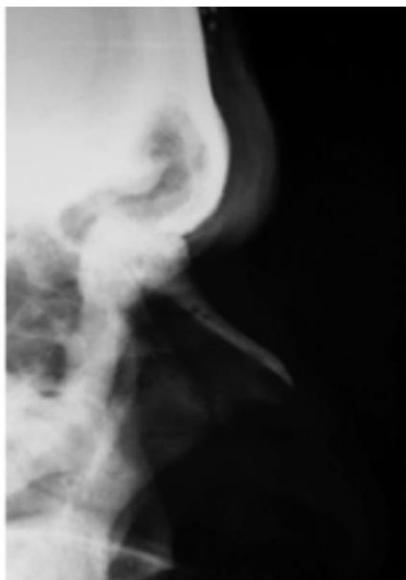Another boy name Hasan age 12 years injured in RSA was brought to a doctor in his private clinic. The boy was complaining of vomiting, vertigo and had severe pain at neck and head regions. It was medicolegal, the X -Ray report was greivous due to a depressed fracture at the temporal bone. As it was medico legal case so he was brought to hospital. The father of the patient was insisting for admission and asking for MLC opinion. To evaluate the case the CMO on duty advised CT scan. The CT confirmed neither fracture nor any other lesion. The MLC report was changed from GREVIOUS to SIMPLE.



X Ray doubtful fracture



CT confirmed fracture of calcanium and other metatarsals



Nasal bone seen normal in X Ray but CT confirms hairline fracture

50 SUCH CASES

A study of 50 medico legal cases having both X Ray and CT scan revealed the following.

- 1, Number of cases 50
- 2, Sex 35 male, 15 female
- 3, Age From 3 years to 45 years.
- 4, Region of trauma different regions but mostly skull Comparison of Reports of X Ray and CT divided in three groups.

GROUP A

X Ray report normal but CT confirmed fracture 8 cases, 16 %

GROUP B

X Ray report fracture but CT excluded the lesion 12 cases, 24 %

GROUP C

X Ray report and CT reports were the same 30 cases, 60 %

RESULTS

Computerized Tomography [CT] is the best confirmation in bone fracture. In medicolegal cases

apart from treatment point of view even a minor bone fracture has great importance. CT is helpful to confirm X –Ray reports in doubtful hair line fracture specially in organs with overlapping bones e.g., skull and also in old cases where union has started.

CONCLUSION

X Ray should be the first tool of diagnosis in all bone trauma including MLC cases. However suspected cases to be confirmed on CT images and if available on 3D CT reconstruction.

Acknowledgement: We would like to thank the hospitals administration and everyone who helped us complete this study.

Disclaimer: Nil

Conflict of Interest: There is no conflict of interest.

Funding Disclosure: Nil

Authors Contribution

Concept & Design of Study: Abdul Aziz Zia

Drafting: Abdul Aziz Zia

Data Analysis: Abdul Aziz Zia

Critical Review: Abdul Aziz Zia

Final Approval of version: Abdul Aziz Zia



Open Access: This article is licensed under a Creative Commons Attribution 4.0 International License, which permits use, sharing, adaptation, distribution and reproduction in any medium or format, as long as you give appropriate credit to the original author(s) and the source, provide a link to the Creative Commons license, and indicate if changes were made. The images or other third party material in this article are included in the article's Creative Commons license, unless indicated otherwise in a credit line to the material. If material is not included in the article's Creative Commons license and your intended use is not permitted by statutory regulation or exceeds the permitted use, you will need to obtain permission directly from the copyright holder. To view a copy of this license, visit <http://creativecommons.org/licenses/by/4.0/>. © The Author(s) 2020