

HISTOPATHOLOGICAL PATTERNS OF TESTICULAR BIOPSY IN MALE INFERTILITY IN KHYBER PAKHTUNKHWA, PAKISTAN

Mohammad Manzoor¹, Mohtasimbillah¹, Shagufta Nasir Parvez², Sardar Ahmad³, Nuzat Khattak³

¹Department of Pathology, Bacha Khan Medical College, Mardan, Pakistan

²Institute of Kidney Diseases, Hayatabad, Peshawar, Pakistan

³Department of Physiology, Bacha Khan Medical College, Mardan, Pakistan

⁴Department of Histopathology, Khyber Girls Medical College, Peshawar, Pakistan

ABSTRACT

Objective: *Histopathological alterations found in the testicular biopsies of male infertiles.*

Materials & Methods: *This inscriptional study was carried out between July 2012 and June 2014 in the urology and pathology departments of North West General Hospital and Research Center Peshawar and Rehman Medical Institute Peshawar. There were a total of 71 infertile patients enrolled in this study. The couples underwent a thorough clinical history, physical examination, semen analysis, and hormone analysis before having testicular biopsy. In the lab, biopsies were fixed, processed, stained, and mounted. There were seven histopathological patterns classified. Testicular biopsies were evaluated using the Johnson Score (1–10).*

Results: *This study showed (36.62%) Sertoli cell only syndrome, (62%) maturation arrest, and (19.72%) normal spermatogenesis. Nonobstructive azoospermia cases: 73.24% Obstructive azoospermia cases: 26.76%.*

Conclusion: *The most common pattern in our research is germ cell aplasia or Sertoli cell syndrome, which accounts for 36.62% of all cases.*

Key Words: *FSH, LH, azoospermia, spermatogenesis & infertility*

INTRODUCTION

Testicular biopsy for male infertility is becoming a life-altering event as new technology make it possible for men once thought to be infertile to become fathers. When a woman is unable to conceive after one year of coitus, she is said to be infertile, and when a man is unable to impregnate a fertile woman, he is said to be infertile¹. Male infertility is a widespread issue today. About one-quarter of infertility cases are caused by male factors alone, and another thirty to forty percent have male factors as a contributing component². Most couples conceive within a year of starting trying. Couples who try to conceive but do not succeed within

a year without using contraception may be infertile in 15-20% of cases³. There are three potential origins: pre-, during-, and after-testis. Male infertility may have pre-testicular reasons, such as a lack of gonadotropins, alcohol, genetic disorders, and smoking. Age, Y chromosome defects, an abnormal set of chromosomes, Klinefelter syndrome (47, XXY, or XYY), neoplasm, e.g. seminoma, cryptorchidism, varicocele; trauma; mumps; USP26 defects; acrosomal defects; idiopathic oligospermia; and radiotherapy are all major causes of male infertility. Medical history, a physical exam, semen analysis, blood hormone analysis, vasography, and a testicular biopsy are all used to diagnose male infertility. Post-testicular causes include a lack of Vas deferens, a blocked ductus deferens, inflammation of the prostate and other infections, impotence, congenital defects of the urethra, abnormal ejaculation, and a blocked ductus ejaculatorii⁵.

MATERIAL & METHODS

From July, 2012 through June, 2014, researchers gathered data for this descriptive study. We looked at

Correspondence:

Dr. Mohammad Manzoor

Assistant Professor

Department of Pathology,

Bacha Khan Medical College, Mardan, Pakistan

Cell: 0346-9345360

Email: drmohammadmanzoor@yahoo.com

Citations : Mohammad Manzoor, Mohtasimbillah, Shagufta Nasir Parvez, Sardar Ahmad, & Nuzat Khattak. (2020). HISTOPATHOLOGICAL PATTERNS OF TESTICULAR BIOPSY IN MALE INFERTILITY IN KHYBER PAKHTUNKHWA, PAKISTAN: Original Article. Journal of Bacha Khan Medical College, 1(01), Page No. 42–45.
<https://doi.org/10.69830/jbkmc.v1i01.81>

data from 71 male patients who had diagnostic testicular biopsies performed at North West General Hospital & Research Center Peshawar and Rehman Medical Institute Peshawar, with a mean age of 34.300. 7 years. Patients with azoospermia on semen analysis who sought treatment at the urology clinics of North West General Hospital & Research Center Peshawar and Rehman Medical Institute Peshawar had tissue biopsies taken. Biopsies of both testicles were performed. The patients were then classified into one of seven groups:

1. Those with a Johnson’s score of 10 or 9 have normal spermatogenesis. Problematic situations like these existed.

Cases of Johnson’s score 8 are the most common kind of hypospermatogenesis.

Third, spermatogenesis stops in its tracks in all tubules, usually at the level of the original spermatocyte.

Sertoli cell syndrome 4 is characterized by the absence of germ cells at any developmental stage. The Johnson’s score 1 and 2 are examples of this.

Fifth, hyalinization of the seminiferous tubules causes the loss of the germinal epithelium. Hyalinization occurs extensively both outside and inside of the tubules.

Heterogeneous pattern: the presence of more than one histological type.

Pathological patterns are inconsistent between the two testicular biopsies.

RESULTS

A total of 71 patients were included in the analysis, and their average age was 3.31 1.591 years. Their ages varied from about July 2012 to June 2014, when they averaged out to be about 37.5 years old. Testicular biopsies preceded hormonal and sperm analysis in every case. Analysis of the men’s sperm showed that they all had azoospermia despite having normal levels of FSH, LH, Testosterone, and Prolactine. This study provided more evidence that testicular, rather than pre-testicular, factors were responsible for infertility in our patient population. The histopathological findings from these samples were as follows:

DISCUSSION

Geographical differences in male infertility are significant. Histopathological patterns differ, as shown by several studies. Genetics, social context, and environmental risks such high heat, toxins, radiation, and underlying disorders cause these disparities 7,8. The

Table 1: Outcomes of histopathological finding

S. No.	Histopathological Findings	Johnson’s Score	No. of patients	% of patients
1.	Normal Spermatogenesis	9-10	14	19.72
2.	Hypospermatogenesis	8	9	12.68
3.	Germ Cell Maturation Arrest	3-7	17	23.94 %
4.	Sertoli Cell Only Syndrome	2	26	36.62 %
5.	Tubules Hyalinization		1	01.41 %
6.	Mixed Pattern		1	01.41 %
7.	Discordant Pattern		3	04.23 %

Cases = 72

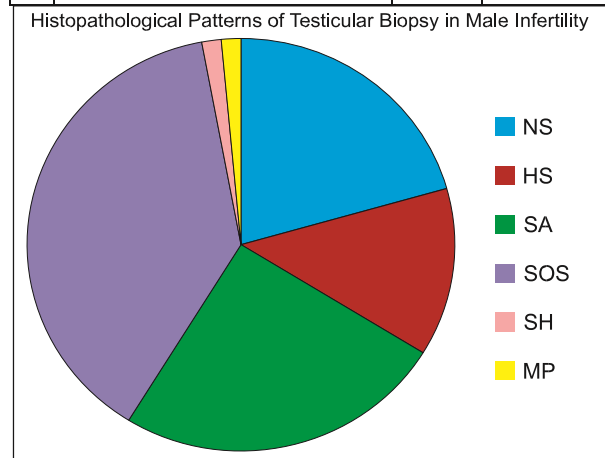
Mean age =03.31

S/D =01.591

Table 2: scoring system of cases based on (Johnson’s Score)

Scoring system for testicular biopsies (Johnson’s Score)	No. of cases	Percentage
10 Spermatogenesis Full	06	08.52
9 Slightly impaired spermatogenesis, disordered epithelium	08	11.70
8 Less than 5 spermatozoa per tubule, Few late spermatids	05	06 , 94
7 No spermatozoa, no late spermatids, many early spermatids	01	01.00
6 No spermatozoa, no late spermatids, few early spermatids	0	00.00
5 No spermatozoa or spermatids, many spermatocytes	0	00.00

4	No spermatozoa or spermatids, few spermatocytes	09	14.29
3	Spermatogonia only	08	12.70
2	No germinal cells, Sertoli cells only	25	41.27
1	No seminiferous epithelium	01	01.58



No obstructive azoospermia = 72%
 Obstructive azoospermia = 27%

Figure 1: demographically View of Histopathological Patterns of Testicular Biopsy in Male infertility

indications or criteria for the testicular biopsy, the surgeon's expertise, the use of a better fixative (such as Bouin), correct processing, and the histopathologists' knowledge and experience may also alter the statistics.

There are exceptions to my categorization. There is also no quantitative way for labeling a case hypospermatogenic.

I initially classed individuals with Johnsen scores of 9 and 10 as having normal spermatogenesis, which was 19.72%⁸, similar to the mean of studies (21%). Some studies have found higher rates of normal spermatogenesis, but our study found 9 out of 10 males had it. Ragab (24%; 10 cases) and Wong (25%; 11 cases) reported normal spermatogenesis. The Johnson's score showed normal spermatogenesis in 25% of instances by Sadia Qazi, Atif Mazhar, and Surriya Sarwat at Sindh Medical University in Karachi, Pakistan between January 2010 and January 2011¹², and 26% by scientists in Duhok city. 9, 31% by AlRayess et al.¹³, 35% by Brannen and Roth¹⁵, and

38% by Thomas¹⁶. Our estimates for obstructive azoospermia prevalence are high, but Al-Dabbagh reported 17.9% (16), Nagpal et al. 16.0%, Layla Abdullah and Nabeel Bondagji 14%, Haddad and colleagues 11.2%⁵, and Meinhard and colleagues 5%⁶.

Men have 12.68 percent hypospermatogenesis, according to our findings. Most researchers reported higher numbers than we did (3.7%), although Thomas & Jamal reported lower numbers. AlRayess found 13% hypospermatogenesis while Haddad et al. 58%. Sperm cells decrease in hypospermatogenesis.

Germ cell maturation arrest (23.94) was the second most common group after Sertoli cell alone syndrome. Our study found SOS to be the most prevalent histologic subtype (36.62%). Sertoli cell only syndrome was initially reported by AlRayess (39%), Thomas (27.2%), Sadia Qazi in Karachi (2011) (17%), and Layla Abdullah (16%). Unable to explain the discrepancy between these findings. Undiagnosed orchitis, cryptorchidism, or Ubiquitin-specific protease 26 anomalies may explain our region's extremely high Sertoli alone syndrome prevalence. As said, other elements may be involved. Hyalinization of seminiferous tubules was 1% in our study sample. The others had lesser fibrosis than the severe case. Rashed et al. (6%), Layla Abdullah (16%), Alsamawi (19.2%), AlRayess (5.21%), Nagpal (13%), Thomas (22.4%), and Jamal (24%), described seminiferous tubule hyalinization. The variation across studies may be due to surgeons using different criteria when opting to biopsy. Inflammation or orchitis may produce seminiferous tubule halinization.

Mixed pattern is common, however our investigation found only one instance (0.41%). The optimum diagnosis for mixed and discordant cases is a bilateral biopsy.

Just 3% of 52 bilateral biopsies yielded different outcomes. Total proportion was 4.2. Layla Abdullah found 10% of patterns incorrect. McLachlan et al.'s study of 534 bilateral testicular biopsies showed the importance of bilateral biopsies for infertile male diagnosis and ICSI.

Germ cell aplasia or Sertoli cell alone syndrome is the most common morphology in our sample (36.62 percent). Our research explains why a bilateral testicular biopsy is suggested for male infertility

diagnosis. Bilateral biopsy is needed to diagnose discordant or mixed patterns.

REFERENCES

1. Kuang W, Rogers D. A practical approach to testicular biopsy interpretation for male infertility. *Pubmed –NCBI*. 2018; 134: 1197-204
2. Ragab N, Shalaby A, Ragab W. Patterns of testicular histopathology in men with primary infertility. *Int J Urol*. 2018; 5:1-5.
3. De Rooij DG, Keijer J. Functional relationship between obesity and male reproduction: from humans to animal models. *Hum. Reprod. Update*. 2021; 17 (5): 667–83
4. Van Berkel K, Vorrsselmans A, Staessen C., Liebaers I. regnancy outcome in carriers of Robertsonian translocations. *Am J Med Genet Part A*. 2016; 155:2381–2385.
5. Gurevich, Rachel (06-10-2008). “Does Age Affect Male Fertility?”. *About.com:Fertility*. About.com. Retrieved 14 February 2016.
6. Schiff JD, Luna M, Evans MI, Patel Z, Berry PK, Bar-Chama N (April 2019). “Sex chromosome micromosaicism in infertile men with normal karyotypes”. *Fertil. Steril*. 93 (6): 1903–6.
7. Luna M, Finkler E, Barritt J, Bar-Chama N, Sandler B, Copperman AB, Grunfeld L (2019). “Paternal age and assisted reproductive technology outcome in ovum recipients”. *Fertil Steril* 92 (5): 1772–5.
8. Ferreira RC, Braga DP, Bonetti TC, Pasqualotto FF, Iaconelli A, Borges E (2016). “Negative influence of paternal age on clinical intracytoplasmic sperm injection cycle outcomes in oligozoospermic patients”. *Fertil. Steri*. 93 (6): 1870–4.
9. Poongothai J, Gopenath TS, Manonayaki S (2009). “Genetics of human male infertility”. *Singapore Med J* 50 (4): 336–47.
10. Stouffs K, Lissens W, Tournaye H, Haentjens P (2010). “What about gr/gr deletions and male infertility? Systematic review and meta-analysis”. *Human Reproduction Update* 17 (2): 197–209.
11. Alkual JP, Khera M, Wheeler TM (2009) Testicular biopsy in male infertility evaluation. In: *Infertility in the Male*. Cambridge University Press, pp 215-22561.
12. Schoor RA, Elhanbly S, Niederberger CS, Ross LS (2012). The role of testicular biopsy in the modern management of male infertility. *J Urol* 167:197-200
13. Song N, Liu J, An S, Nishino T, Hishikawa Y, Koji T (2011). “Immunohistochemical Analysis of Histone H3 Modifications in Germ Cells during Mouse Spermatogenesis”. *Acta Histochemica et Cytochemica* 44: 183–90
14. Saleh R, Mahfoz RZ, Agarwal A, Farouk H (2010). Histopathological patterns of testicular biopsies in infertile azoospermic men with varicocele. *Fertil Steril* 94: 2482-5, 2485
15. Pasqualotto FF, Fonseca GP, Pasqualotto EB (2008). “Azoospermia after treatment with clomiphene citrate in patients with oligospermia”. *Fertility and Sterility* 90 (5).
16. Traber MG, Stevens JF (2011). “Vitamins C and E: Beneficial effects from a mechanistic perspective”. *Free Radical Biology and Medicine* 51 (5): 1000–13.
17. Lombardo F, Sansone A, Romanelli F, Paoli D, Gandini L, Lenzi A (2011). “The role of antioxidant therapy in the treatment of male infertility: An overview”. *Asian Journal of Andrology* 13 (5): 690–7.
18. Ghanem H, Shaer O, El-Segini A (2010). “Combination clomiphene citrate and antioxidant therapy for idiopathic male infertility: A randomized controlled trial”. *Fertility and Sterility* 93 (7): 2232–5.
19. Abu Elhija M, Lunenfeld E, Schlatt S, Huleihel M (2011). “Differentiation of murine male germ cells to spermatozoa in a soft agar culture system”. *Asian Journal of Andrology* 14 (2): 285–93.
20. S, Q, A M, S S (2013). “Histomorphological patterns of testicular biopsies in azoospermic infertile males from a tertiary care unit of Pakistan”. *Med. Forum* 24(4):26-30.

Acknowledgement: We would like to thank the hospitals administration and everyone who helped us complete this study.

Disclaimer: Nil

Conflict of Interest: There is no conflict of interest.

Funding Disclosure: Nil

Authors Contribution

Concept & Design of Study: Mohammad Manzoor1,

Drafting: Sardar Ahmad3

Data Analysis: Nuzat Khattak3

Critical Review: Sardar Ahmad3,

Final Approval of version: Mohammad Manzoor1,



Open Access: This article is licensed under a Creative Commons Attribution 4.0 International License, which permits use, sharing, adaptation, distribution and reproduction in any medium or format, as long as you give appropriate credit to the original author(s) and the source, provide a link to the Creative Commons license, and indicate if changes were made. The images or other third party material in this article are included in the article's Creative Commons license, unless indicated otherwise in a credit line to the material. If material is not included in the article's Creative Commons license and your intended use is not permitted by statutory regulation or exceeds the permitted use, you will need to obtain permission directly from the copyright holder. To view a copy of this license, visit <http://creativecommons.org/licenses/by/4.0/>. © **The Author(s) 2020**