

POSITION OF APPENDIX AND ITS RELATED MORBIDITY

Usman Ali¹, Ashab Noor², Waqar Alam Jan³, Muhammad Islam⁴, Abdus Samad Khan⁵, Mumtaz Khan³

¹Department of Anatomy, Bacha Khan Medical College, Mardan, Pakistan

²Department of Urology, Postgraduate Medical Institute, Lady Reading Hospital, Peshawar, Pakistan

³Department of Surgery, Postgraduate Medical Institute, Lady Reading Hospital, Peshawar, Pakistan

⁴Department of Surgery, Nowshera Medical College, Nowshera, Pakistan

⁵Department of Surgery, Rehman Medical College, Peshawar, Pakistan

ABSTRACT

Introduction: The most frequent surgical emergency is appendicitis. Traditional symptoms and indicators may vary depending on where the appendix is located.

Objective: The goal of this research is to understand the numerous ways that appendicitis manifests, as well as the associated morbidity and mortality. **Material and methods:** From January 2008 to March 2008, this research was carried out at the surgical 'A'

Unit at Lady Reading Hospital in Peshawar. The research was designed in a descriptive manner. After a thorough history, investigation, and operation, patients who arrived at the emergency room were assessed. The location of the appendix was recorded along with other findings.

100 patients were assessed after being hospitalized. There were 32% women and 68% men. The most frequent position during surgery was the retrocaecal position (78%) followed by pelvic position (16% of cases). Three individuals (all with retrocaecal appendix) had perforated appendices. **Conclusion:** Patients who presented to emergency as having appendicitis most often had retrocaecal appendix (78%). Less symptoms/signs cause issues and a delay in diagnosis.

Key words: appendicitis, retrocaecal appendix. Position of appendix.

INTRODUCTION

The most frequent surgical emergency is appendicitis.¹ Due to different presentations, particularly in the location of the appendix, that vary from the normal indications of appendicitis, accurate identification is often hampered. Traditional descriptions of the position of the appendix include retrocaecal, pelvic, paracaecal, pre-, and post-ileal.² The chance of complications like perforation, which is linked to an increase in morbidity and death, rises with a delay in diagnosis and treatment. Because the appendix is obstructed, the pain of acute appendicitis is often characterized as colicky at first in the

paraumbilical (epigastric) area. After a while, the discomfort moves to the right lower quadrant because the parietal peritoneum is being irritated by the inflamed appendix. Vomiting and nausea are frequent. Because an inflamed appendix irritates the rectum in instances of pelvic appendix, diarrhea may happen. Fever of low degree is typical with appendicitis. The McBurney's pain, or the intersection of the lateral one-third and medial two-thirds, is where there is the most soreness. Tenderness extends higher and more laterally than this in instances with retrocaecal appendix. Rectangular soreness may be seen in pelvic appendicitis. The discomfort guarding may only be present in the right lower quadrant of a localized ruptured appendix. The abdomen is painful and guarded in widespread appendicitis caused by a ruptured appendix. The anatomic location of the inflamed appendix and whether or not the organ has been reported being ruptured at the time of the

Correspondence:

Usman Ali

Asstt. Professor and Head Department of Anatomy,
Bacha Khan Medical College, Mardan, KPK, Pakistan

Cell: 0333-9135453

Email: usalikhan60@yahoo.com

Citations: Usman Ali, Ashab Noor, Waqar Alam Jan, Muhammad Islam, Abdus Samad Khan, & Mumtaz Khan. (2020). POSITION OF APPENDIX AND ITS RELATED MORBIDITY: Original Article. Journal of Bacha Khan Medical College, 1(01), Page No. 30-34. <https://doi.org/10.69830/jbkmc.v1i01.78>

patient's first examination dictate the majority of the physical findings.

The purpose of our research was to investigate the signs and symptoms of patients who were examined, to mark the location of the appendix after surgery, and to track morbidity and death.

MATERIAL AND METHODS

From January 2008 to March 2008, this research was carried out at the surgical 'A' Unit at Lady Reading Hospital in Peshawar. All patients who arrived at the emergency room were checked after a thorough history was taken. A probe was done into the patient. All patients underwent TLC, urine, erect abdominal X-rays, and abdominal ultrasonograms. The patient was enrolled in the trial after receiving a definitive diagnosis of acute appendicitis. The research excluded patients who had widespread peritonitis as a result of a ruptured appendix. His indications and symptoms were meticulously documented when individuals were included in the trial. The research did not include patients who were unsuitable for general anesthesia. Otherwise, all patients were included in the investigation. Patients who had right lower quadrant discomfort from reasons other than appendicitis were also not included in the research. After being admitted, patients had general anesthetic preparation before being operated on as quickly as possible in the emergency room, with the location of the appendix being noted on the chart. All of the findings were ultimately analyzed, contrasted, and drawn.

RESULTS

100 patients in total were assessed. In terms of gender, 68% of patients were men and 32% were women (Graph No. 1). The majority of patients (72%) reported right iliac fossa discomfort that had lasted one day. Eight (8%) individuals (Table

Table No. 1: The presentation's symptoms (n=100)

Duration	No. of patients	Percentage
01 day	72	72 %
01 week	08	08 %
02 weeks	20	20 %
TOTAL	100	100%

Table No. 2: The presentation's signage (n=100)

Signs	No. of patients	Percentage
Non-shifting pain right iliac fossa (RIF)	55	55 %
Shifting pain right iliac fossa (RIF)	45	45 %
Pain from epigastrium	25	25 %
Pain from umbilical region	20	20 %

Table No. 3: Appendix position during surgery (n=100)

Symptoms	No. of cases	Percentage
Maximum tenderness at Mc-Burney's point	100	100 %
Tenderness at McBurney's point and above (3 cm)	08	08 %
Tenderness at McBurney's point and below (3 cm)	10	10 %

Table No. 4: Findings of related conditions while under general anesthesia (n=100)

Position of appendix	No. of patients	Percentage
Retrocaecal	78	78 %
Pelvic	16	16 %
Preileal/postileal	06	06 %
TOTAL	100	100 %

Table No. 5: Associated Condition of patients and percentage

Associated conditions	No. of patients	Percentage
Perforated appendix	03	03 %
Pregnancy	01	01 %
Meckal's diverticulum	01	01 %

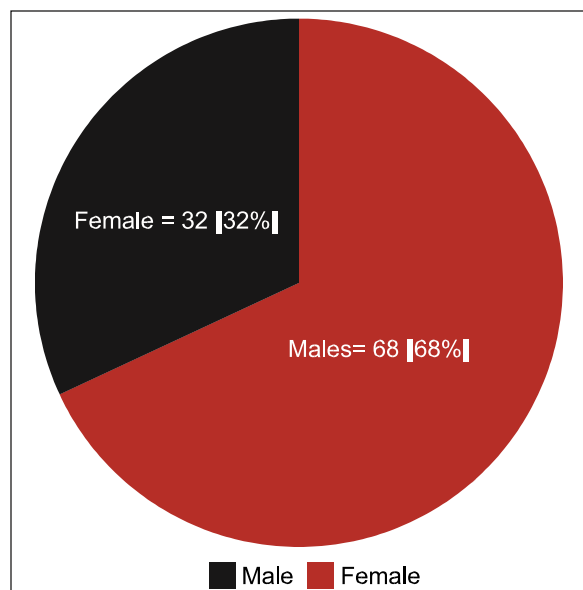


Figure 1: Gender-Wise Distribution of Patients (N=100)

No. 1) reported having discomfort for one week. The age range was 13 to 45. The 100 patients all reported right iliac fossa discomfort at presentation. 45 patients (45%) reported with varying discomfort coming from the umbilical area (20 patients) and the epigastrium (25 individuals). Therefore, the majority of the patients—55 (55%) patients—presented with right iliac fossa non-shifting discomfort (Table No. 2). Upon inspection, McBurney's point was the site of greatest discomfort for all 100 patients. Eight individuals exhibited 4 cm of soreness above McBurney's point. At the time of operation, all eight patients had a retrocaecal appendix. Maximum soreness was seen in eleven patients at McBurney's point and four centimeters below. Of the 10 patients, 6 had pelvic appendices, whereas the remaining 4 had retrocaecal appendices (Table No. 3). Retrocaecal position was the most frequent during surgery in 78 (78%) instances. In 16 (16%) patients, the appendix was located in the second-most frequent location in the pelvis (Table No. 4). One patient had Meckel's diverticulum, and one patient had pregnancy, both of which were discovered after surgery. Three individuals had perforated appendices during surgery. The retrocaecal appendix was seen in all 3 individuals (Table No. 5).

DISCUSSION

The most frequent surgical emergency is appendicitis. Due to the location of the appendix,

different presentations that vary from normal indicators may sometimes lead to a correct diagnosis. Increased morbidity and mortality result from delayed diagnosis and treatment. Preileal (1), Postileal (5), Paracaecal (2), and Retrocaecal (74) are some of the positions that the appendix has been reported in.² Early detection of appendicitis is crucial because it may reduce morbidity and death via timely treatment or surgery. Appendicitis is mostly diagnosed clinically. Appendicitis may be identified by radiologists thanks to advances in ultrasound methods. They may observe a blind terminated gut loop with an incompressible lumen by using graded compression methods. Graded compression ultrasonography is one of the novel diagnostic methods that has reportedly improved clinical outcomes and diagnostic precision.³ The light reveals a facecloth. In acute appendicitis, the diameter exceeds 6 mm.⁴ On ultrasonography, even a ruptured appendix might seem as a lumen discontinuance at a particular location. In a research by Wieysma, F5 ultrasonography was able to view 82% of asymptomatic children's appendices, and it was also able to record the diameter and lumen of the appendix as well as its location. By using improved multi detector-row CT, Miki T and colleagues⁴ found that acute appendicitis could be distinguished from normal with 99% accuracy. They had 92% accuracy in diagnosing gangrenes, 84% in phlegmonous conditions, and 92% in acute catarrhal conditions. Appendiceal wall thickness, an appendicolith, a filthy fat sign localized ascites, and an abscess were discovered on the CT scan. Focused appendiceal CT approaches, which enable quick patient scanning and little patient exposure and expense, have been found to have the highest CT accuracy. The use of a CT scan decreased the incidence of false-positive diagnoses for acute appendicitis, resulting in a 20% reduction in the rate of negative appendicitis operations and a 4% drop in perforation rates. According to Asma and Shaista⁶, a ruptured appendix had a sensitivity of 69% and a specificity of 97%. A 64-year-old man with an appendix rupture and intestinal malrotation was the subject

of a case report by Lin CJ and colleagues⁷. The condition was discovered on a CT abdominal scan since the patient had unusual symptoms. In order to diagnose acute appendicitis, laparoscopy should be utilized often.⁸ According to Negelli J and colleagues⁹, diagnosis accuracy with laparoscopy is about 100%,

making it possible to prevent needless appendectomies.⁹

Less normal appendectomies are performed as a result of laparoscopy, especially in women who are fertile and for whom the diagnosis may not be certain.¹⁰ It is still unclear what function laparoscopy plays in the treatment of severe appendicitis, such as gangrenous perforated appendicitis.¹¹ Routine laparoscopy and laparoscopic appendix removal for suspected acute appendicitis are safe and significantly reduce hospital stays.¹²

Ages ranged from 13 to 45 years for the 68 male and 32 female patients in our research.

The age range recorded by Nazir Ahmad and associates¹³ was 13 to 75 years old, with 51% men and 49% women. 42% of men and 57% of women, according to Singhen and associates¹⁴. In our research, 8 individuals sought medical attention after a week from the time their symptoms began, whereas 72% of patients sought medical attention within 24 hours. Regarding symptoms, 100% of the patients experienced the most discomfort at McBurney's point and all patients reported right iliac fossa pain. In our investigation, retrocaecal, pelvic, preileal, and paracaecal infections affected 78% of the patients. At a laparoscopy, Ahmad and associates¹⁵ reported the location of the appendix. Their findings were as follows: retrocaecal 20.1%, postileal 22%, preileal 8%, paracaecal 3.6%, pelvic 51%. They came to the conclusion that retrocaecal is less prevalent than pelvic position. In a research by Cleg-Lumptey and colleagues¹⁶, the findings showed that 67.3% of cases were retrocaecal, 21.6% were pelvic, 4.9% were preileal, 3.8% were postileal, and 2.4% were paracaecal. According to their findings, the retrocaecal location is the most typical and the appendix is less likely to inflame in this position. (A cadaveric investigation showed a retrocaecal position of 67.37 and acute appendicitis showed a retrocaecal position of 56.7%). Pelvic position (33.3%) was found to be the most common by Golalipour and colleagues¹⁷, followed by retrocaecal (32.4%), preileal (18.8%), and subcaecal (12.8%). According to a study by Mohammad Ahmad and colleagues¹⁸, the retrocaecal position is

one of the most typical (79%) and is followed by the pelvic position (21%). They came to the conclusion that retrocaecal location was more prevalent in advanced appendicitis. When researching the causes of appendix rupture in the elderly, Sheu BF and

colleagues¹⁹ came to the conclusion that the retrocaecal appendix was a significant contributor, along with age, the severity of the pain, the time between admission and operation, and fever. According to Chan et al.²⁰, the retrocaecal and retroileal placements caused doctors to take longer to obtain a diagnosis. One patient in our research was seven months pregnant. There was no peak in discomfort or change in the appendix's location. Researchers Hadjati H12 and Kazerooni T21 found no evidence of the appendix shifting location during pregnancy. In our research, all patients had right iliac fossa discomfort, although 25% of patients report-

ed experiencing epigastric pain initially and 20% reported experiencing peri-umbilical pain first. The McBurney's point was sensitive for every patient, although 8% of patients also had tenderness 3 cm above the McBurney's point. It was discovered that all of these patients had retrocaecal appendicitis. 4% of patients had additional tenderness at the McBurney's site. Six of them had a pelvic appendix, whereas four of them had a retrocaecal appendix. Six individuals in our research had discomfort R.I.F. repeatedly. All of these patients were discovered to have retrocaecal appendices. All three of the patients who had perforated appendices when they first appeared were retrocaecal. In addition to making appendicitis diagnosis challenging, retrocaecal appendix, according to Mohammad Ahmad and associates⁹, is more susceptible to infection, perforation, and gangrene. In our research, there was no fatality.

CONCLUSION

Regardless matter where the appendix is, McBurney's location has the most soreness. The most typical place for an appendix is retrocaecal. Early diagnosis of retrocaecal, particularly high retrocaecal, is exceedingly challenging. More difficulties arise as a result of delayed diagnosis. (We often see gangrene retrocaecal appendix). The key to diagnosis is frequent inspection and evaluation while keeping in mind the different locations of the appendix and associated consequences. If at all feasible, an abdominal CT scan should be performed in every instance of appendicitis. As it informs us not only about the appendix's irritation but also about its location, a well-planned incision may be made.

REFERENCES

1. Chen CW, Hsiao CW, Wu CC, Jao SW, Lee TY, Kang JE. Necrotizing fasciitis due to acute perforated appendix. J Emerg Med 2008; Jan 26.

2. O'Connell PM. The vermiform appendix. In: Russel RCA, Williams NS, Christopher JK, Blustrode CJK, eds. Bailey and Love's short practice of surgery. 25th ed. London: Arnold, 2008:1203.
3. Mardan MAA, Mufti TS, Khattak IUD, Chilkunda N, Alshayeb AA, Mohammad AM, et al. Role of ultrasound in acute appendicitis. J Ayub Med Coll Abbottabad 2007;19:72-9.
4. Miki T, Ogata S, Uto M, Nakazono T, Urata M, Ishibe R, et al. Enhanced multi-detector-row computed tomography (MDCT) in the diagnosis of acute appendicitis and its severity. Radiat Med 2005;23:242-55.
5. Wiersma F, Sramek, Holschev HC. US features of normal appendix and surrounding area in children. Radiology 2005;235:1018-22.
6. Siddiqui AA, Afzal S. Perforated appendicitis: accuracy of CT diagnosis and correlation of CT findings with the length of hospital stay. J Coll Physicians Surg Pak 2007;17:721-5.
7. Lin CJ, Tiu CM, Chou YH, Chen JD, Liang WY, Chang CY. CT presentations of ruptured appendicitis in an adult with incomplete intestinal malrotation. Emerg Radiol 2004;10:210-2.
8. Lally KP, Cox CS, Andrassy RJ. Appendix. In: Townsend CM, Beauchang RD, Evers BM, Mattox KI, eds. Sabiston's textbook of surgery: the biological basis of modern surgical practice. 17th ed. Philadelphia: Saunders, 2004:1381-99.
9. Nageli J, Zund M, Lange J. Laparoscopic diagnosis in suspected acute appendicitis. Hev Chiz Acta 1994;60:787-91.
10. Pirro N, Berdah SV. Appendicitis; yes or no to laparoscopic approach. J Chir (Paris) 2006;143:155-9.
11. Yau KK, Siu WT, Tang CN, Yang GP, Li MK. Laparoscopic versus open appendectomy for complicated appendicitis. J Am Coll Surg 2007;205:60-5.
12. Yong JL, Law WL, Locy, Lam CM. A comparative study of routine laparoscopic vs open appendectomy. JSLS 2006;10:188-92.
13. Ahmad N, Abid KJ, Khan AZ, Shah STA. Acute appendicitis – incidence of perforated appendicitis. Ann KE Med Coll 2004;10:356-8.
14. Singhai TV. Acute appendicitis are we over-diagnosing. Ann R Coll Surg Engl 2007;89:766-9.
15. Ahmad I, Asgeirsson KS, Beckingham IJ, Lobo DN. Position of vermiform appendix at laparoscopy. Surg Radiol Anat 2007;29:165-8.
16. Clegg-Lumptye JN, Avmahit, Macede SB, Adu-Avyce NA. Position and susceptibilities to inflammation of vermiform appendix in Accra Ghana. East Afr Med J 2006;83:670-3.
17. Gotalipour MJ, Arupa B, Azarhoosh, Jahanshahi. Anatomical variations of vermiform appendix in South East Caspian Sea (Gorgan Iran). J Anat India 2003;52:141-3.
18. Ahmad M, Ahmad I, Gill KM. Retrocaecal appendix. Professional Med J 2002;9:135-8.
19. Sheu BF, Chiu TF, Chen JC, Tung MS, Chang MW, Young YR. Risk factors associated with perforated appendix in elderly patients presenting with signs and symptoms of acute appendicitis. ANZ J Surg 2007;77:662-6.
20. Wai-To C, Hau-Yin NC, Kwan-Chui C, Kit-Ting CK, Mam-Hung C, Kar-Huen HK, et al. Does appendix position affect the clinical outcome of acute appendicitis? Surg Pract 2002;6:109-12.
21. Hodjati H, Kozeroni T. Location of appendix in the gravid patients; are evolution of established concept. Int J Gynaecol Obstet 2003;81:245-7.

Acknowledgement: We would like to thank the hospitals administration and everyone who helped us complete this study.

Disclaimer: Nil

Conflict of Interest: Nil.

Funding Disclosure: Nil

Authors Contribution

Concept & Design of Study: Usman Ali1

Drafting: Ashab Noor2

Data Analysis: Muhammad Alam3

Critical Review: Usman Ali1, Waqar Alam Jan3

Final Approval of version: Usman Ali1, Mumtaz Khan3



Open Access: This article is licensed under a Creative Commons Attribution 4.0 International License, which permits use, sharing, adaptation, distribution and reproduction in any medium or format, as long as you give appropriate credit to the original author(s) and the source, provide a link to the Creative Commons license, and indicate if changes were made. The images or other third party material in this article are included in the article's Creative Commons license, unless indicated otherwise in a credit line to the material. If material is not included in the article's Creative Commons license and your intended use is not permitted by statutory regulation or exceeds the permitted use, you will need to obtain permission directly from the copyright holder. To view a copy of this license, visit <http://creativecommons.org/licenses/by/4.0/>. © The Author(s) 2020