

## Original Article

**EXTERNAL OBLIQUE HERNIOPLASTY AN EARLY EXPERIENCE IN TERTIARY CARE UNIT**Usman Ali<sup>1</sup>, Naik Zada<sup>2</sup>, Muhammad Hussain<sup>3</sup><sup>1</sup>Department of Anatomy, Bacha Khan Medical College, Mardan, Pakistan<sup>2</sup>Department of Anatomy, Saidu Medical College, Swat, Pakistan<sup>3</sup>Department of Surgery, Bacha Khan Medical College, Mardan, Pakistan**ABSTRACT**

**Background:** The most frequent general surgical operation is the correction of an inguinal hernia. The most often used method for open inguinal hernia surgery is Lichtenstein tension-free repair. The gold standard for inguinal hernia repair is the endoscopic surgery known as TEP, TAPP, and Lichtenstein repair. The posterior wall of the inguinal canal is strengthened via external oblique hernioplasty, which uses the Apo neurosis of the external oblique muscle. The study's objectives were to document the problems of the novel procedure and evaluate the outcomes against gold standard practices.

**Objectives:** To evaluate the viability and effectiveness of external oblique hernioplasty compared to conventional inguinal hernia repair techniques. It also attempts to compare the results of this new operation with well-established methods like TEP, TAPP, and Lichtenstein procedures, concentrating on recovery timeframes, long-term success rates, and postoperative discomfort.

**Study design:** A descriptive study

**Duration and place of study:** MMC Mardan from June 2015 till June 2016

**Materials and Methods:** The descriptive research design was used, and it took place at MMC Mardan between June 2015 and June 2016. An informed consent was obtained about the surgery. Following studies, the patient's circumstances were optimized before surgery. The trial covered all individuals who were deemed suitable for general anaesthesia. A single surgeon operated on each patient, and any postoperative problems were noted. Every patient was monitored for one month.

**Results:** All 57 patients who had surgery for inguinal hernias were men. Urinary retention affected 14% of patients in the first postoperative week. 7% of patients reported having SSI, while 14% of patients reported having chronic discomfort. The best option is still mesh repair. A deeper comprehension of the issue has led to an improvement in failure rates. Male patients are often affected by inguinal hernias. There have been conflicting reports on urinary retention and discomfort during the first postoperative week. In mesh repairs, seromas are more frequent. The rates of scrotal oedema were higher than those of mesh repairs.

**Conclusion:** Regarding the immediate postoperative period, the procedure's outcomes are similar to mesh repairs.

Long-term issues such as recurrence are anticipated.

**Correspondence: Usman Ali**

Associate Professor, Department of Anatomy,  
Bacha Khan Medical College, Mardan, Pakistan

**Email:** usalikhan60@yahoo.com

Cell: 03339135453

**Date Received:** Jan-05-2021

**Date Accepted:** Feb-07-2021

**Citations :** Usman Ali, Naik Zada, & Muhammad Hussain. (2021). EXTERNAL OBLIQUE HERNIOPLASTY AN EARLY EXPERIENCE IN TERTIARY CARE UNIT: Original Article. Journal of Bacha Khan Medical College, 2(01), Page No. 21–26. <https://doi.org/10.69830/jbkmc.v2i01.49>

**INTRODUCTION**

Inguinal Hernia repair is the most frequently performed surgical procedure worldwide in general surgery <sup>1</sup>. Inguinal hernia repair is the most common general surgical procedure in industrialized countries, with a frequency of about 200 operations per 100,000 persons per year <sup>2</sup>.

The repair process might be minimally intrusive or open. For open inguinal hernia surgery, the most often used method is Lichtenstein tension-free repair <sup>3</sup>. The endoscopic process TAPP, TEP, and open methods Guidelines from the European Hernia Society and the European Association of Endoscopic Surgery propose Lichtenstein, plug and patch, and PHS as the gold standard for inguinal hernia repair <sup>4</sup>. The external oblique muscle's aponeurosis is used in external oblique hernioplasty to reinforce the inguinal

canal’s posterior wall. The gold standard in open inguinal hernia surgery is Lichtenstein repair, often known as mesh repair. This research aimed to find outcomes for cost-benefit postoperative complications and hospital stays that are on par with or better than a gold standard.

Following herniotomy, external oblique aponeurosis reinforces the inguinal canal’s posterior wall. This treatment involves an incision similar to mesh repair (inguinal incision). The external oblique is exposed up to 4 cm above the inguinal ligament, and the nerves that travel across it are dissected and retracted. An incision is made 1.5–2 cm above the inguinal ligament for the external oblique. After the chord is cut, a herniotomy is done. Nonabsorbable sutures attach the top leaf of the external oblique to the posterior lip of the inguinal ligament, posteriorizing the anterior wall. The exterior oblique leaf sutured is cut 3–4 cm above the sutured line. Nonabsorbable sutures are also used to suture the top incised border of the external oblique, creating a broad band of external oblique aponeurosis that spans the inguinal canal’s posterior wall. The top, non-sutured leaf of the external oblique is attached to the bottom border of the oblique by sutures. This process replaces the inguinal canal’s weak posterior wall with a strong, durable layer. Hence, the body’s tissues are used instead of foreign material, as in mesh repair.

**MATERIAL AND METHODS**

The primary goal was to reduce mesh costs while maintaining equal outcomes and minimizing problems. The descriptive research design was used, and it took place at MMC Mardan between June 2015 and June 2016. After obtaining a complete medical history, every patient who presented as an outpatient with an inguinal hernia was hospitalized. Following admission, procedure-related informed consent was obtained. Before surgery, the patient’s comorbid diseases were cared for and optimized. Patients were admitted without regard to their gender. Patients who did not meet the inclu-

**Table 1: Showing gender distribution**

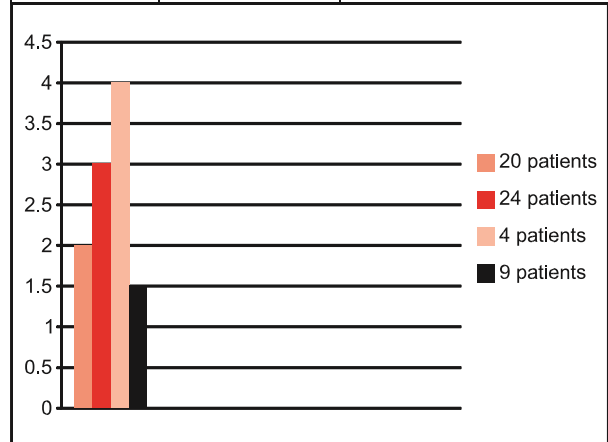
Male	Female
57	0

**Table 2: Showing the distribution of type and side of a hernia**

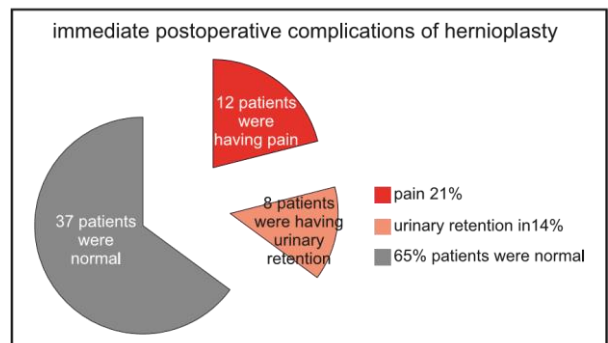
Indirect hernia RT	30 Patients	52 %
Indirect hernia LT	7 Patients	12 %
Direct hernia RT	12 Patients	22 %
Direct hernia LT	3 Patients	5 %
Recurrent hernia RT	5 Patients	9 %
Bilateral hernia	0 Patients	0%

**Table 3: Age wise distribution of type of a hernia**

Age Range	No. of patients	Type of hernia
15-20 years	22 pts (38%)	Indirect hernia
21-30 years	17 pts	Mixed hernia (direct and indirect)
31-40 years	10 pts	Mixed hernia (direct and indirect)
41-50 years	5 pts	Mixed hernia (direct and indirect)
51-55 years	3 pts	Direct hernia



**Fig 1: Showing number of patients and their stay in the hospital**



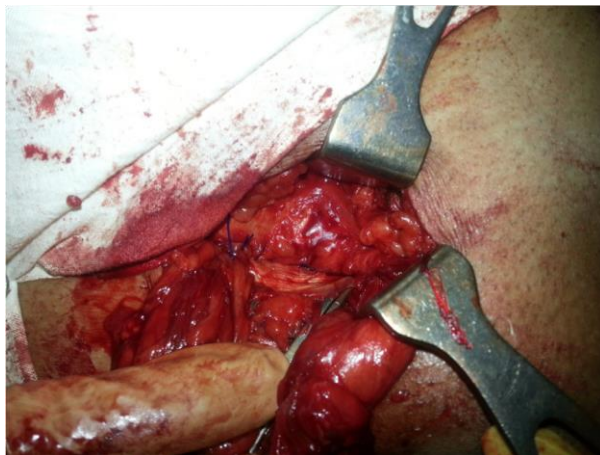**Fig 2: Showing immediate postoperative complications in hernioplasty**  
 sion criteria for general anaesthesia were not allowed to participate in the research. The research included

patients with direct inguinal hernias with substantial defects that required mesh treatment, as well as those with weak abdominal walls. Routine examinations of the patient's chest, complete blood count, and blood sugar levels were performed. In some instances, lung function tests, an ECG, and an ECHO were conducted.

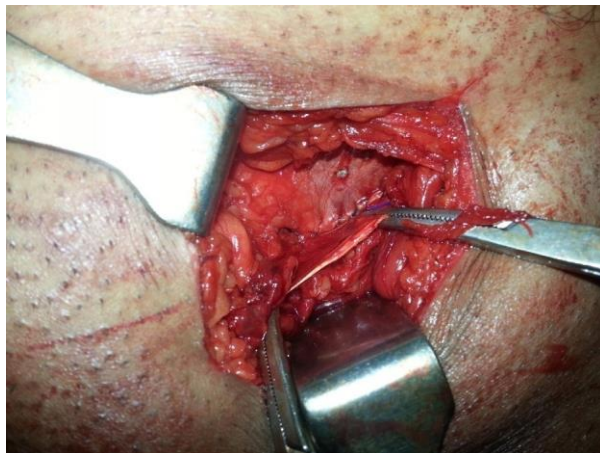
A single surgeon operated on each patient to

variables, including operating time, immediate

postoperative problems, and early postoperative

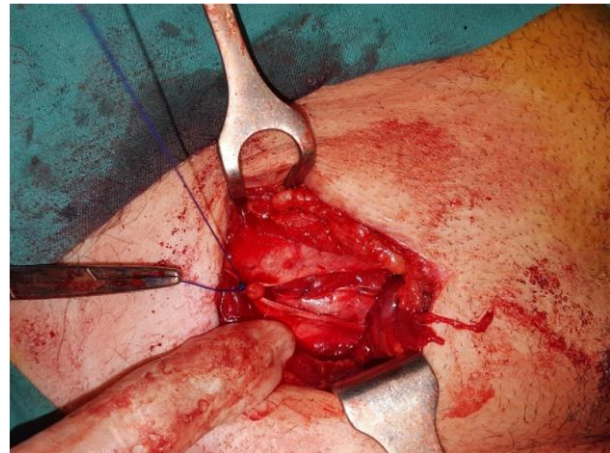


This picture shows an artery clamp applied to the inguinal ligament and bulging weak posterior wall of inguinal canal above the inguinal ligament



This picture shows upper leaf of external oblique eliminate any bias, and data was collected on several

posterior wall of inguinal canal with lower edge sutured to the inguinal ligament and upper edge sutured to the roof of the inguinal canal. This repair creates a stronger posterior wall than mesh repair



This picture shows closure of external oblique aponeurosis while in between the two leaves of external oblique the band of external oblique strengthening the posterior wall of inguinal canal is clearly visible

Every issue was noted, processed, and contrasted with mesh repair issues found in other publications.

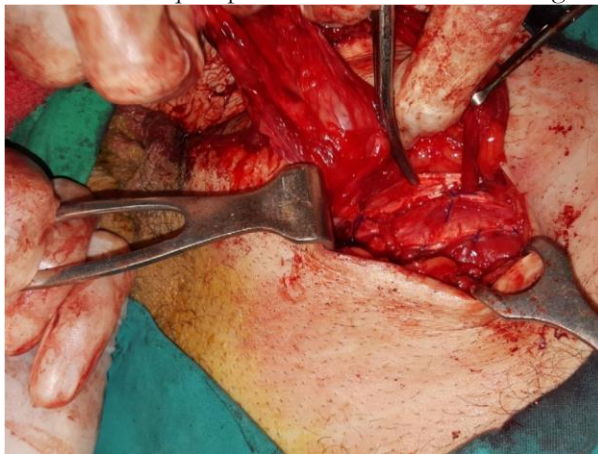
**RESULTS**

At MMC Mardan, external oblique hernioplasty was done on 57 patients. Male patients only presented with an inguinal hernia issue. The majority of patients had an indirect inguinal hernia. In contrast, 8.7% of patients had a recurrence hernia. The average age of presentation in our research was 26 years old. The surgery took 47+/-10 minutes on average. A minimum difficulties. The patients were monitored for one

month. sutured to the inguinal ligament and artery

clamp applied to lower leaf of external oblique. The

bulging posterior wall is now supported by tough external oblique aponeurosis as there is no bulge



This picture shows a band of external oblique across of 1.5 and 4 days were spent in the hospital, with an average stay of 2.5 days. The average time to return to work for patients who worked for themselves was 10 days, and for those who worked for someone else, it was twenty-two days. Urinary retention affected 14% of patients, and discomfort affected 21% in the first postoperative week. Early postoperative discomfort (10%) and scrotal oedema (8%), in particular, were significant evaluation tools. In the last postoperative phase, 14% of our patients had chronic pain, and 7% had SSI. After a month of observation, there was no recurrence.

## DISCUSSION

Mesh open or endoscopic repair remains gold standard <sup>4</sup> with the the least complications and variable cost. Eighty-two per cent of surgeons use the tailored approach, the differential use of several hernia repair techniques depending upon the findings of patients<sup>4</sup>. Given that the pathophysiology of the illness includes an anomaly of the extracellular matrix,

the recommendation for a mesh-based repair is typically appropriate. Advancements have markedly improved many patients' prospects in surgical procedures, the creation of novel prosthetic materials, and a deeper understanding of their use<sup>5</sup>. Hernia surgery centres have shown the greatest improvement in failure rates; some of these facilities claim failure rates of less than 1%.

This research aimed to evaluate external oblique hernioplasty problems and compare them with the results of other tension-free procedures found in the literature. A total of 57 individuals had surgery as part of our research. Every patient in our research was a man<sup>5</sup>. Burcharth J<sup>6</sup> made a similar discovery about the distribution of genders.

Twenty-four per cent of our patients had an indirect hernia. In our analysis, right-sided hernias (52%) predominated. Singh RR<sup>5</sup> noted similar findings about right-sided dominance in inguinal hernias. In our research, 27% of patients had a straight hernia without double inguinal hernias, and 9% of patients had recurring issues. Of the patients in our research, 29% were up to 29 years old, and 38% were up to 20 years old. Younger patients dominated our research.

The age range in a different research was 40–50 years old<sup>5</sup>. The mean age was 56, according to Saxena et al. The surgery took 47+10 minutes on average. According to Saxena et al., the typical surgery took 57 minutes.<sup>7</sup> Papazioqas reported an operating duration of 75+/-10 minutes<sup>8</sup> for open mesh repairs. The average operation, according to Karaca AS, was 53+\_32 minutes.

Urinary retention and discomfort were the first postoperative problems in 14% and 21% of our patients, respectively<sup>5</sup>. Singh RR found that 4% and 8% of patients had urine retention and discomfort, respectively. Urinary retention was found by Saxena et al. in 6% of individuals who had spinal anesthesia<sup>7</sup>. Salma U noted that throughout both open and endoscopic procedures, the majority of her patients complained of pain<sup>10</sup>. According to Reiner MA, 4% of patients had urine retention <sup>11</sup>.

In 6% of our patients, we saw bleeding and bruises that improved with conservative therapy. 4% of patients had ecchymosis, according to Saxena et al <sup>7</sup>. We detected seroma and hematoma in 6% of our patients. Seroma was noted in 12% of Singh RR's patients <sup>5</sup>. Of his patients, 4% had seroma, according

to Saxena et al<sup>7</sup>. Reiner MA said that 3% of patients had seromas<sup>11</sup>. In 8% of our patients, scrotal oedema was seen. Reiner MA saw scrotal edema in 2% of his patients<sup>11</sup>. Singh RR noted scrotal edema in 4% of his patients<sup>5</sup>.

Four incidences of superficial wound infection occurred in our study. There were no deep tissue infections found. According to Singh RR, the infection rate was 4%, which improved with cautious measures and mesh preservation. According to Reiner MA, the infection was 0.1%, and there were no mesh removal cases<sup>11</sup>. Although prior research has shown that obese individuals had higher morbidity after open surgeries, Froylich et al. concluded that the current data indicate that laparoscopic surgery was associated with a lower risk of deep operative site infection<sup>12</sup>. Zhang, who was overweight and in the open repair group, had a deeper SSI. According to Willoughby AD, the open repair group had higher overall morbidity than the laparoscopic repair group<sup>13</sup>.

According to Karaca AS, individuals who are obese and having laparoscopic repairs have a lower risk of developing profound SSI or wound dehiscence of our patients, six had chronic discomfort. They are resuming regular activities sooner after laparoscopic repairs, which are linked to decreased discomfort and numbness after the procedure<sup>14</sup>. In 2.8% of his patients, Huang CS found persistent, incapacitating discomfort after PHS repairs<sup>15</sup>. He also concluded that prolene hernia system repair is quicker to execute, has a lower risk of small wound infection, and allows for a speedy return to normal activities. Writers have been figuring out new ways to lessen the depressing sensation of chronic pain. Although the evidence is not strong enough, some writers suggest laparoscopic surgeries as a preventative measure against persistent pain. The invention of sutureless, self-gripping, and self-adhesive mesh is an attempt to eliminate persistent discomfort during open or laparoscopic procedures. After mesh repairs, Stay et al. found that an ultrasound-guided nerve block technique improved pain control<sup>16</sup>.

There was no hernia recurrence in our study. Recurrence was noted in 1.7% of elective and 2.3% of emergency patients by Peitsch.<sup>17</sup> In our setup, all were admitted to the patient department with no

emergency patients. Wujj concluded that elective hernia repairs in the elderly have similar mortality as compared to the general population in contrast to emergency surgery, which carries high mortality<sup>18</sup>. Bucharth J reported an overall recurrence rate of 5.2%, while direct hernia recurrence was 11%<sup>19</sup>. A direct hernia, along with female sex and smoking, was a significant factor for recurrence<sup>20</sup>.

## CONCLUSION

A perfect treatment should include less time in the operating room with a quick recovery, the fewest potential problems after surgery, a shorter hospital stay with a quicker return to normal activities, and, most importantly, the lowest hospital costs. There is disagreement among writers over which surgical technique is ideal; some favour open surgeries, while others favour laparoscopic ones. Open mesh repairs are less expensive than laparoscopic operations and take less time.

The outcomes of external oblique hernioplasty are similar to those of open or laparoscopic mesh hernioplasty. Given its cheap cost, it seems appealing. Although more extensive long-term follow-up data is needed, initial findings indicate a bright future.

## REFERENCE

1. Klobusicky P. Usage of self-adhesive mesh in TAPP hernia repair: A prospective study based on Herniated Register, J Minimum Access Surg.2016 July-sept;12(3):226-34. doi:10.4103/0972-9941.181388
2. Berger D. Evidence-Based Hernia Treatment in Adults. DtschArztebl Int.2016 Mar 4;113(9):150-7;quiz 158.doi:
3. Zhang C. Self-gripping versus sutured mesh for inguinal hernia repair: a systematic review and meta-analysis of current literature. J Surg Res 2013 Dec;185(2):653-60.doi: 10.1016 /j.jss 2013.07.035 Epub 2013 Aug 11.
4. Kockerling F. Tailored approach in inguinal hernia repair –decision tree based on the guidelines. Front Surg, 2014 June 20;1:20.doi: 10.3389/fsurg.2014.00020. eCollection2014.
5. Sing RRetal. A Study about Inguinal hernia mesh repairs: plug and patch versus Lichtenstein mesh repair technique.I nt. Surg.J.2016 Nov;3(4):1967-1974

6. Pradeep Saxena. A prospective comparative study of Lichtenstein mesh hernioplasty performed under local and spinal anaesthesia. *Int.J.*2016 Aug;3(3):1477-1485
7. Burcharth J. The epidemiology and risk factors for recurrence after inguinal hernia surgery. *Dan Med J*, 2014 May .61(5):B4846
8. Papazioqas B et al. Tension-free repair versus modified Bassini technique for strangulated inguinal hernia: a comparative study. *Hernia* 2005 May;9(2):156-9. Epub 2005 Feb 3.
9. Karaca AS. Comparison of inguinal hernia repairs performed with Lichtenstein, Rutkow-robbins and Gilbert double layer graft method. *Indian J Surg.*2015 Feb;77(1):28-33. doi:10.1007/s12262-013-0809-4. Epub 2013 Jan 16.
10. Salma U. A comparison of postoperative pain and hospital stay between Lichtenstein's repair and Laparoscopic Transabdominal preperitoneal ( TAPP) repair of hernia: A randomized controlled trial. *Pak j Med Sci* 2015 sept;31(5): 1062. doi:12669/pjms.315.4811.
11. Reiner MA. Laparoscopic Total Extraperitoneal Hernia Repair Outcomes. *JLS.*2016 Jul-sep;20(3). pii:e2016.00043. doi:10.4293/JLS.2016.00043
12. Frohlich D et al. Laparoscopic versus open inguinal hernia repair in obese patients: an American College of Surgeon NSQIP clinical outcomes analysis. *SurgEndosc* 2016 Jul 21. [Epub ahead of print ]
13. Willoughby AD. Open versus laparoscopic unilateral inguinal hernia repairs: defining the ideal BMI to reduce complications. *SurgEndosc.*2016 May 18. [Epub ahead of print]
14. McCormack K et al. Laparoscopic surgery for inguinal hernia repair: systematic review of effectiveness and economic evaluation. *Health Technol Assess.*2005 Apr;9(14):1-203, iii-iv
15. Huang CS. Prolene hernia system compared with mesh plug technique: a prospective study of short- to mid-term outcomes in primary groin hernia repair. *Hernia* 2005 May;9(2):167-71. Epub 2005 Feb 10.
16. Stay A et al. Transversus Abdominis plane versus Ilioinguinal and Iliohypogastric Nerve Blocks for Analgesia Following Open Inguinal Herniorrhaphy. *Rambam Maimonides Med J.* 2016 Jul 28;7(3). Doi: 10.5041/RMMJ. 10248
17. Peitsch WK. A modified laparoscopic hernioplasty (TAPP) is the standard procedure for inguinal and femoral hernias: a retrospective 17-year analysis with 1,123 hernia repairs. *SurgEndosc.*2014 Feb;28(2):671-82. doi:10.1007/s00464013-3208-9. Epub 2013 Sep 17.
18. Wu JJ. Should we perform elective inguinal hernia repair in older people? *Hernia* 2016 Jul 20. [Epub ahead of print]
19. Burcharth J. Direct inguinal hernias and anterior surgical approach are risk factors for female inguinal hernia recurrences. *Langenbecks Arch Surg* 2014 Jan;399(1):71-6.
20. Burcharth J. Patient-related risk factors for recurrence after inguinal hernia repair: a systematic review and meta-analysis of observational studies. *Surginnov.*2015 Jun;22(3):30317. doi: 10.1177/1553350614552731. Epub 2014 Sep 30.

**Disclaimer:** Nil

**Conflict of Interest:** There is no conflict of interest.

**Funding Disclosure:** Nil

**Authors Contribution**

**Concept & Design of Study:** Usman Ali1,

**Data Analysis:** Naik Zada2

**Critical Review:** Muhammad Hussain3

**Final Approval of version:** Usman Ali1,



**Open Access:** This article is licensed under a Creative Commons Attribution 4.0 International License, which permits use, sharing, adaptation, distribution and reproduction in any medium or format, as long as you give appropriate credit to the original author(s) and the source, provide a link to the Creative Commons license, and indicate if changes were made. The images or other third party material in this article are included in the article's Creative Commons license, unless indicated otherwise in a credit line to the material. If material is not included in the article's Creative Commons license and your intended use is not permitted by statutory regulation or exceeds the permitted use, you will need to obtain permission directly from the copyright holder. To view a copy of this license, visit <http://creativecommons.org/licenses/by/4.0/>. © The Author(s) 2021