

Case Report

A CASE REPORT ON RUPTURED RUDIMENTARY HORN PREGNANCY AT 16 WEEKS WITHOUT THE PAST 2 NORMAL VAGINAL DELIVERIES

Nuzhat Amin, Zara, Samia

Department of Gynecology, Bacha Khan Medical College, Mardan, Pakistan

ABSTRACT

a unicornal uterus with a primitive horn, it means that the contralateral side did not fuse properly with the other side, and one of the Mullerian ducts did not fully develop. It is quite uncommon to get pregnant with a noncommunicating rudimentary horn, and most pregnancies end in rupture in the first or second trimester. It might be challenging to diagnose primitive horn pregnancy and its rupture in a woman who has had a vaginal birth in the past. Regular ultrasound scans may miss it; in most cases, the rupture leads to its discovery. A strong index of suspicion is necessary. We reported a case of G3P2 with a ruptured rudimentary horn pregnancy at 16 weeks of gestation. The ultrasound incorrectly identified the pregnancy as an intrauterine one with fetal demise, and an attempt at termination was made. The patient was subsequently referred to our hospital when hemoperitoneum and shock were observed, along with a diagnosis of a ruptured uterus. Upon laparotomy, a rupture of the right rudimentary horn and significant hemoperitoneum were discovered. An early laparotomy, horn removal, and blood transfusion saved the patient.

Study design : A CASE REPORT

INTRODUCTION

Buttram and Gibbons first categorized Mullerian abnormalities in 1979, and the American Society of Reproductive Medicine changed the classification once again in 1988. The unicornuate uterus, categorized as type 2, has unilateral hypoplasia or agenesis. It may be further divided into noncommunicating, communicative, cavity-free, and horn-free categories¹. In the normally fertile population, the incidence of uterine congenital abnormalities resulting from Mullerian deficiencies is 3.2%. 2.4%–13% of all Mullerian abnormalities are caused by a unicornuate uterus². The cavity is not in communication with 72–85% of the primitive horns³. A unicornuate uterus with a primitive horn may be linked to obstetric and

gynecological complications, such as endometriosis, hematometra, infertility, abnormalities of the urinary system, abortions, and premature births. The most feared complication that might endanger a mother's life during pregnancy is rupture. We describe a case of an attempted abortion due to fetal death in which a ruptured rudimentary horn pregnancy was mistaken for an intrauterine pregnancy and occurred in shock at 16 weeks of gestation.

CASE REPORT

At midnight, a 30-year-old G3P2 woman who was 16 weeks pregnant and diagnosed with a ruptured uterus was sent from a remote health facility to our hospital's emergency room. Our hospital, Mardan Medical Complex Hospital, which is a part of Bacha Khan Medical College, mostly serves people living in rural areas. The woman's prior vaginal delivery went well. She was pregnant for the third time. She visited a remote primary health care facility for prenatal visits. At 16 weeks pregnant, she went for an ultrasound because she was experiencing abdominal discomfort and there were no fetal movements. A 16-week intrauterine fetal death was discovered during the peripheral

Correspondence:

Dr. Nuzhat Amin

Associate Professor,

Department of Gynecology

Bacha Khan Medical College, Mardan, Pakistan.

Email:k.shahbaz50@yahoo.com

Cell: 0316-9001827

Date Received: Jan-05-2021

Date Accepted: Feb-07-2021

Date Revised: Mar-24-2021

Available Online: April-03-2021

center's ultrasonography evaluation. The woman was given misoprotol induction to stimulate the fetus's ejection in light of the fetal death. Twelve hours after her induction, she had tachycardia, hypovolemia, shock, and hypotension. These characteristics led to the diagnosis of a ruptured uterus, and our hospital was consulted for further care.

Upon assessment, the woman had a fast, weak pulse, significant pallor, and was in hypovolemic shock. There was no way to record her blood pressure. The uterine size could not be seen, and the abdomen seemed stiff and swollen. Upon pelvic examination, there was cervical movement pain and fornix fullness. No vaginal bleeding was seen. After resuscitation, the patient was sent immediately for a laparotomy due to her shock. She had 3 grams of hemoglobin when she had her laparotomy.

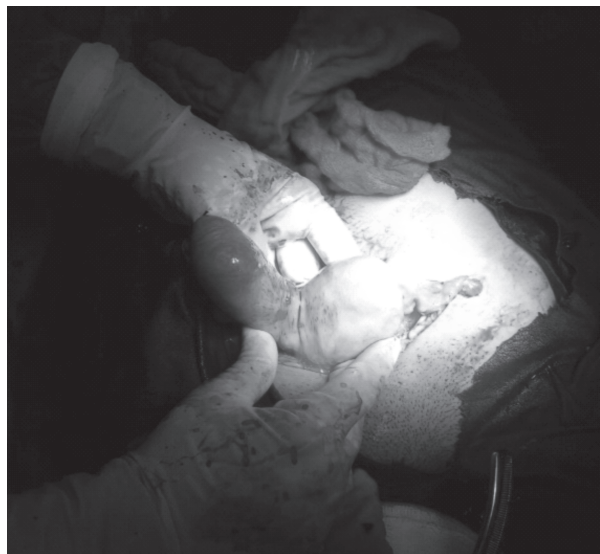

Figure 1: Rupture right rudimentary horn

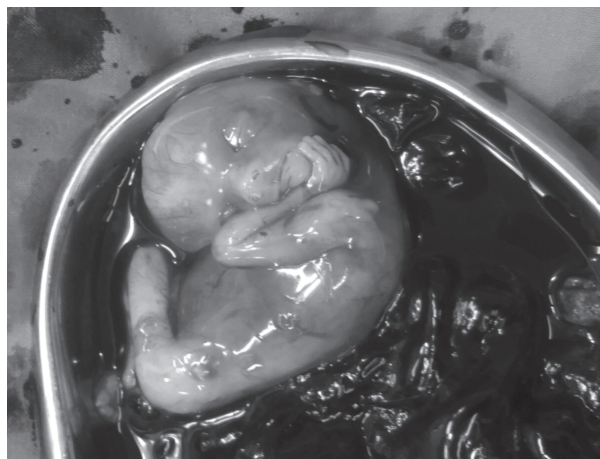


Figure 2: Fetus with placenta and clots

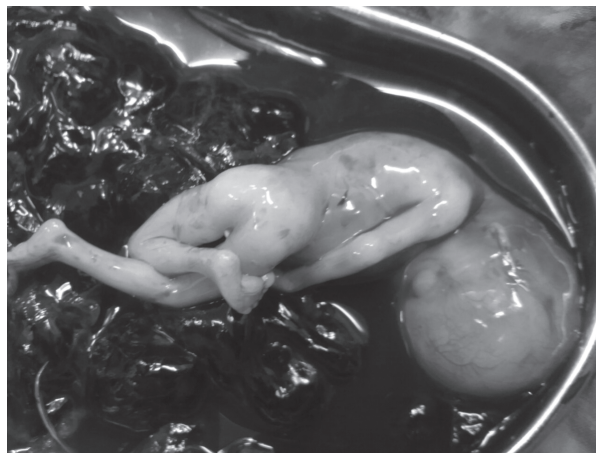

Figure 3: Fetus with placenta and clots

The right rudimentary noncommunicating horn of the unicornuate uterus ruptured during the laparotomy (Figure 1). This let the fetus and placenta float freely in the peritoneal cavity and caused about three liters of hemoperitoneum (Figure 2). About 600 grams was the fetus's weight (Figure 3). The crude horn was removed. The abdomen was kept drained and then closed in layers until hemostasis was achieved. Five blood units were transfused into the woman. She made a wonderful recovery after her surgery. Later, when her urinary system was examined, no abnormalities were discovered. After eight days in the hospital after her surgery, she was released.

DISCUSSION

A basic horn with a unicornuate uterus forms when the contralateral side doesn't fuse properly and one of the Mullerian ducts doesn't fully develop.

According to estimates, the incidence is one per 100,000 to 140,000 pregnancies³. The transperitoneal migration of the fertilized ovum, or the transperitoneal migration of the spermatozoon, causes pregnancy in a noncommunicating primitive horn⁴. Mauriceau recorded the first instance of uterine rupture linked to primitive horn in 1669⁵. Depending on the horn muscle's capacity for hypertrophy and dilatation, the rupture may occur anywhere between five and thirty-five weeks from now. Before 20 weeks, 70–90% burst, which may be disastrous⁶. The bleeding in a rudimentary horn pregnancy rupture is more severe because of the thicker and more vascular uterine wall⁷. Pregnancy is most seriously threatened by rudimentary horn rupture, which may be fatal, according to Kadan and Romano⁸. Prior to 1900, the rate of maternal mortality was 47.6%. Although horn ruptures are still

frequent, there haven't been any documented cases of maternal deaths since 1960⁹. It might be difficult to diagnose the illness early, but early detection is crucial. Diagnostic instruments include laparoscopy, MRI, hysteroscopy, and hysterosalpingogram¹⁰. Fedele et al. reported that ultrasonography was helpful in the diagnosis¹¹. However, ultrasonography sensitivity is only 26%, and it becomes less sensitive as the pregnancy goes on¹². In unskilled hands, like ours, it might be overlooked. Sonographic misinterpretation of abdominal, tubal, cornual, and intrauterine pregnancy is often seen¹³. The expanding horn with a thinning myometrium might hide the neighboring anatomic structures, making diagnosis challenging. There are no clear clinical criteria to identify this life-threatening illness in an emergency.

Tsafir et al. described two instances of primitive horn pregnancies found during the first trimester by sonography and confirmed by MRI. In the rudimentary horn, they described a series of criteria for identifying pregnancy¹⁴. The three characteristics are as follows: (1) an unevenly shaped bicornuate uterus pseudopattern; (2) no clear continuity tissue around the cervix of the uterus and the gestational sac; and (3) myometrial tissue around the gestational sac. However, the majority of cases go undiagnosed until they burst and become emergencies. There have been cases of uterine rupture due to delayed or incorrect diagnoses. When used to end a pregnancy in a primitive horn, labor induction drugs are ineffective and may cause the horn to burst. Due to a mistake, Samuels and Awonuga¹⁵ reported rupture after the administration of misoprostol. This also occurred in our situation. A significant degree of suspicion should be used when looking into nonrespondents to induced abortions. According to Buntungu et al., a sixth-graduation woman who had previously had all normal births was diagnosed with an intrauterine fetal death after an unsuccessful misoprostol induction attempt raised the possibility of an ectopic pregnancy¹⁶.

Surgical excision is the main therapeutic approach for primitive horn⁹. There have been cases of laparoscopic removal of primitive horns and early diagnosis. By using the suprapubic laparoscopic port, Dicker et al. were able to extract a small, primitive horn¹⁷. Yoo et al. [18] laparoscopically removed a pregnant horn that measured cm. Yahata et al.¹⁹ utilized an endoscopic stapler to cut through a fibrous ring that connected the uterus to the rudimentary horn. There is also in-

formation about medical care with methotrexate and laparoscopic removal of the tumor. A case identified by Edelman et al. during the first week of pregnancy was effectively treated with methotrexate²⁰.

Even in situations where there is no rupture, most doctors advise immediate surgery following a diagnosis¹². It is also recommended to get the horn removed before becoming pregnant in order to avoid difficulties. However, in a small number of carefully chosen instances, conservative therapy has been recommended until viability is attained if emergency surgery is available whenever needed and the patient is well-informed⁹. There is documentation of one instance when a cesarean section was necessary to achieve a live delivery after the pregnancy progressed to the third trimester²¹. Since renal abnormalities are discovered in 36% of cases¹², further evaluation of these women is important.

CONCLUSION

Laparotomy is the confirming diagnosis in cases where prenatal diagnosis is still difficult, despite advancements in ultrasonography and other diagnostic modalities. With ultrasonography, particularly by inexperienced operators, the diagnosis might go unnoticed. Due to a delayed or incorrect diagnosis, valuable time may be wasted, and as in our instance, the patient's overall health may become worse. To rescue the patient, prompt resuscitation, surgery, and blood transfusion are required. To lower patient morbidity and death, appropriate diagnostic techniques and prompt referrals from outlying hospitals are required. More people need to be aware of this condition, particularly in underdeveloped nations where it is unlikely that a woman would be detected before becoming pregnant or before her rupture and when valuable time is spent getting her to the referral hospital.

REFERENCES

1. C. H. C. Hassan, A. Kadir, A. Karim, N. A. M. Ismail, and M. H. Omar, "Case report of ruptured non-communicating right rudimentary horn pregnancy: an acute emergency," *Acta Medica*, vol. 54, no. 3, pp. 125–126, 2011. View at Google Scholar · View at Scopus
2. C. Simon, L. Martinez, F. Pardo, M. Tortajada, and A. Pellicer, "Mullerian defects in women with normal reproductive outcome," *Fertility and Sterility*, vol. 56, no. 6, pp. 1192–1193, 1991. View at Google Scholar · View at Scopus

3. H. K. Sevtap, A. M. Aral, and B. Sertac, "An early diagnosis and successful local medical treatment of a rudimentary uterine horn pregnancy: a case report," *Archives of Gynecology and Obstetrics*, vol. 275, no. 4, pp. 297–298, 2007. View at Publisher · View at Google Scholar · View at Scopus
4. M. Scholtz, "A full-time pregnancy in a rudimentary horn of the uterus," *British Journal of Obstetrics & Gynaecology*, vol. 58, pp. 293–296, 1951. View at Google Scholar
5. F. Mauriceau, *Traite des malades des femmes grosses*, vol. 1, Compaigne des libraries, Paris, France, 1721.
6. J. L. O'leary and J. A. O'leary, "Rudimentary horn pregnancy," *Obstetrics and Gynecology*, vol. 22, pp. 371–374, 1963. View at Google Scholar · View at Scopus
7. S. Chowdhury, T. Chowdhury, and E. Azim, "Pregnancy in a non-communicating rudimentary horn of uterus: a clinical case report," *Bangladesh Medical Journal*, vol. 39, no. 1, pp. 47–48, 2010. View at Google Scholar
8. Y. Kadan and S. Romano, "Rudimentary horn pregnancy diagnosed by ultrasound and treated by laparoscopy—a case report and review of the literature," *Journal of Minimally Invasive Gynecology*, vol. 15, no. 5, pp. 527–530, 2008. View at Publisher · View at Google Scholar · View at Scopus
9. G. Nahum, "Rudimentary uterine horn pregnancy: the 20th-century worldwide experience of 588 cases," *Journal of Reproductive Medicine*, vol. 47, no. 2, pp. 151–163, 2002. View at Google Scholar · View at Scopus
10. B. P. Lawhon, J. R. Wax, and R. T. Dufort, "Rudimentary uterine horn pregnancy diagnosed with magnetic resonance imaging," *Obstetrics and Gynecology*, vol. 91, no. 5, p. 869, 1998. View at Publisher · View at Google Scholar · View at Scopus
11. L. Fedele, M. Dorta, P. Vercellini, D. Brioschi, and G. B. Candiani, "Ultrasound in the diagnosis of subclasses of unicornuate uterus," *Obstetrics and Gynecology*, vol. 71, no. 2, pp. 274–277, 1988. View at Google Scholar · View at Scopus
12. Y. Jayasinghe, A. Rane, H. Stalewski, and S. Grover, "The presentation and early diagnosis of the rudimentary uterine horn," *Obstetrics and Gynecology*, vol. 105, no. 6, pp. 1456–1467, 2005. View at Publisher · View at Google Scholar · View at Scopus
13. F. Bahadori, S. Borna, T. Behroozlak, S. Hoseini, and H. Ayatollahi, "Failed induction in second trimester due to pregnancy in an uncommunicated rudimentary horn: case report," *Journal of Family and Reproductive Health*, vol. 3, no. 3, pp. 95–97, 2009. View at Google Scholar
14. A. Tsafirir, N. Rojansky, H. Y. Sela, J. M. Gomori, and M. Nadjari, "Rudimentary horn pregnancy: first-trimester prerupture sonographic diagnosis and confirmation by magnetic resonance imaging," *Journal of Ultrasound in Medicine*, vol. 24, no. 2, pp. 219–223, 2005. View at Google Scholar · View at Scopus
15. T. A. Samuels and A. Awonuga, "Second-trimester rudimentary uterine horn pregnancy: rupture after labor induction with misoprostol," *Obstetrics and Gynecology*, vol. 106, no. 5, pp. 1160–1162, 2005. View at Google Scholar · View at Scopus
16. K. A. Buntungu, M. Y. Ntummy, E. O. Ameh, and S. A. Obed, "Rudimentary horn pregnancy: pre-rupture diagnosis and management," *Ghana Medical Journal*, vol. 42, no. 2, pp. 92–94, 2008. View at Google Scholar
17. D. Dicker, S. Nitke, A. Shoenfeld, B. Fish, I. Meizner, and Z. Ben-Rafael, "Laparoscopic management of rudimentary horn pregnancy," *Human Reproduction*, vol. 13, no. 9, pp. 2643–2644, 1998. View at Publisher · View at Google Scholar · View at Scopus
18. E. H. Yoo, S. H. Chun, and B. H. Woo, "Laparoscopic resection of a rudimentary horn pregnancy," *Acta Obstetrica et Gynecologica Scandinavica*, vol. 78, no. 2, pp. 167–168, 1999. View at Google Scholar · View at Scopus
19. T. Yahata, T. Kurabayashi, H. Ueda, S. Kodama, T. Chihara, and K. Tanaka, "Laparoscopic management of rudimentary horn pregnancy: a case report," *Journal of Reproductive Medicine for the Obstetrician and Gynecologist*, vol. 43, no. 3, pp. 223–226, 1998. View at Google Scholar · View at Scopus
20. A. B. Edelman, J. T. Jensen, D. M. Lee, and M. D. Nichols, "Successful medical abortion of a pregnancy within a noncommunicating rudimentary uterine horn," *American Journal of Obstetrics and Gynecology*, vol. 189, no. 3, pp. 886–887, 2003. View at Publisher · View at Google Scholar · View at Scopus
21. J. W. Shin and H. J. Kim, "Case of live birth in a non-communicating rudimentary horn pregnancy," *Journal of Obstetrics and Gynaecology Research*, vol. 31, no. 4, pp. 329–331, 2005. View at Publisher · View at Google Scholar · View at Scopus